

Closed pure total talar dislocation, open reduction assisted by bone distractor: a case report

Hesham Mohamed Elbaseet, MD and Mohamed Yahya Hassanein, MSc

Orthopedic and Traumatology Department, Assiut University Hospital, Assiut, Egypt

INTRODUCTION

Total dislocation of the talus is very rare. Usually, it is caused by a high-energy trauma where the talus bone dislocates from all surrounding joints (tibiotalar, subtalar, and talonavicular) together with disruption of almost all ligaments and capsular attachments of the talus.¹ Closed dislocations without associated fractures of the malleoli and the talus itself is much more rare.² This report

describes the management, operative details and postoperative regimen for a patient who sustained a high-energy trauma from a motorcycle accident with total dislocation of the talus and without malleolar or talus fractures. Informed consent was obtained from the patient for publication. Institutional review board approval was obtained from the Medical Ethics committee of Assiut University (approval # IRB00009583).

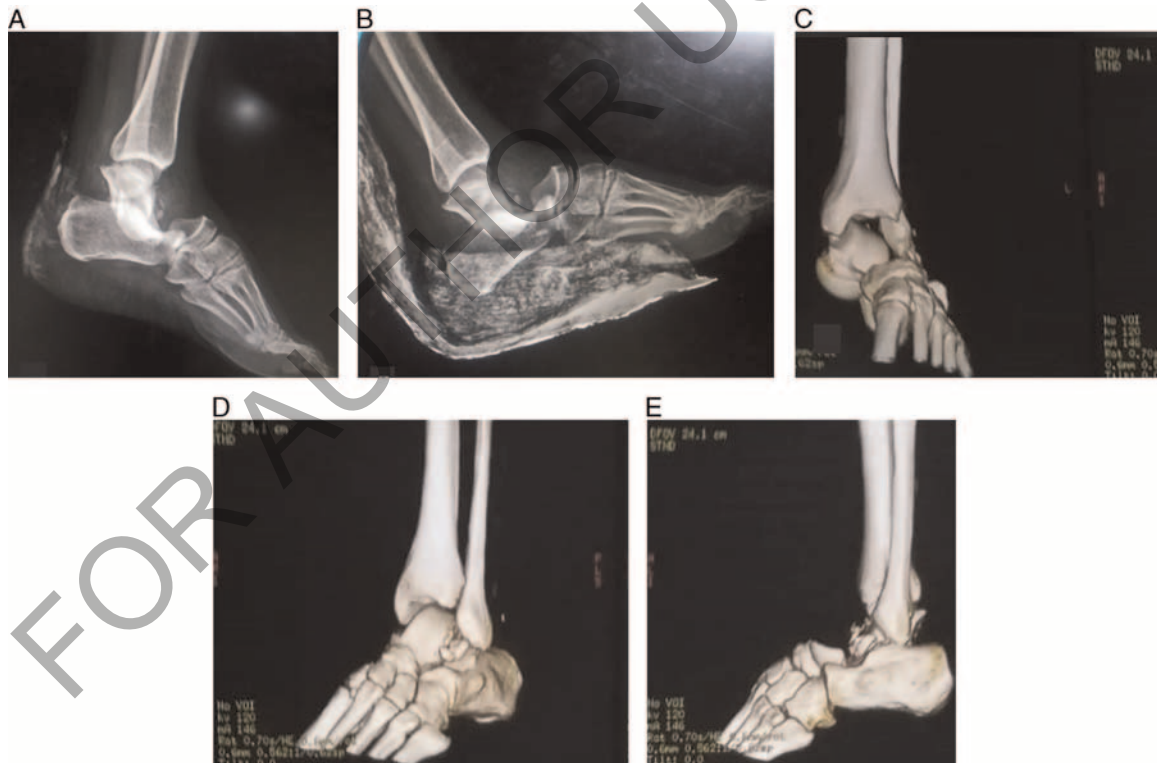


FIGURE 1. Preoperative radiographs (A and B) and preoperative CT scans (C, D, and E) of failure of closed reduction.

Financial Disclosure: The authors report no conflicts of interest.

Correspondence to Hesham Mohamed Elbaseet, MD, Orthopedic and Traumatology Department, Assiut University Hospital, 71515, Assiut, Egypt

Tel: +20 01007780689; fax: +2088/2080278;

e-mail: drhesham20@aun.edu.eg.

1941-7551 Copyright © 2022 Wolters Kluwer Health, Inc. All rights reserved.

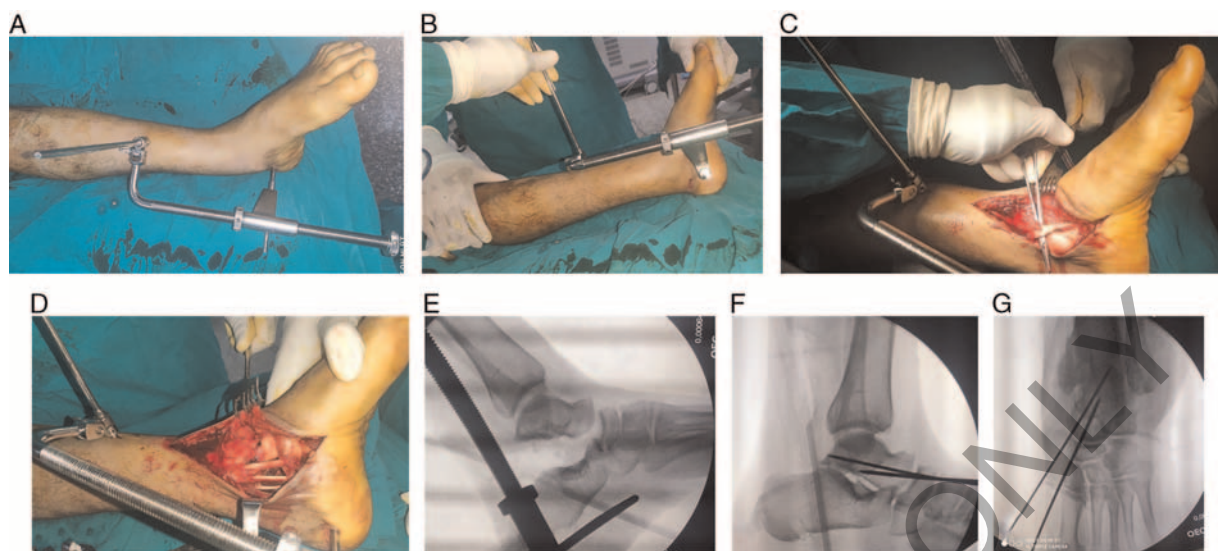


FIGURE 2. Bone distractor application (A and B): one Schanz pin in the calcaneus and another in the tibia. In an anteromedial approach to the foot, buttonholing of the talus between tibialis posterior tendon and flexor digitorum longus tendon is evident (C). Intraoperative photograph (D) and C-arm image (E) after distraction. Concentric reduction was achieved and held with two talonavicular Kirschner wires (F and G).

CASE REPORT

A 32-year-old man was injured in a motorbike accident. Examination revealed a painful, deformed foot without neurovascular compromise or skin bullae. Radiographs and CT scan showed pure lateral dislocation of the talus without evident fractures or other injuries. Closed reduction failed (Figure 1).

The patient was operated 5 hr after the injury occurred. Under spinal anesthesia, a bone distractor was applied. Two threaded Schanz pins were used. The first 5-mm pin was inserted into the calcaneal tuberosity from medial to lateral after locating the posterior tibial pulse. Another 6-mm Schanz pin was inserted into the anteromedial surface of the tibia in the middle of the leg.

Through an anteromedial approach to the foot, buttonholing of the talus between the tibialis posterior tendon and the flexor digitorum longus tendon was observed. Gradual distraction was applied, which facilitated reduction of the talus. Two talonavicular Kirschner wires were inserted to keep reduction (Figure 2). A below-the-knee splint was applied for 1.5 mo.

After treatment by splinting, radiographs showed sound reduction, and the Kirschner wires were removed (Figure 3). The patient was allowed to bear weight with crutches for

another month. At the 1-year follow-up, the patient had no evidence of avascular necrosis of the talus and the Foot and Ankle Disability index³ was 70.2 (Figure 4).

DISCUSSION

Peritalar dislocation is treated first by a trial of closed reduction. If closed reduction fails, no further attempts should be done because soft-tissue entrapment is the cause of irreducibility.⁴ Urgent intervention is mandatory to prevent skin necrosis that is caused by pressure of the dislocated talar head. After reduction, the joint usually is stable because of the fitting of the shape of the articular surfaces. Presence of instability after reduction indicates severe soft-tissue and ligamentous injury that needs repair and secured immobilization by cast or external fixator.⁵

The overall rate of complications is 20% and is directly related to the severity of injury, open injuries, and the extent of the fractures. Postoperative osteonecrosis of the body of the talus and subtalar stiffness are the most common complications.⁶ Instability after reduction is another possible complication, which can be avoided by short-term immobilization.⁷

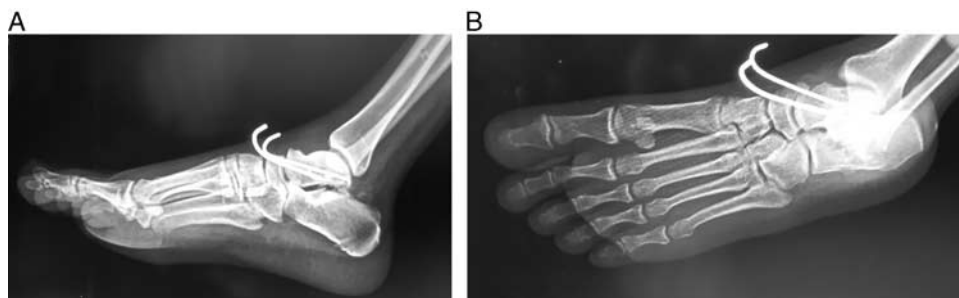

FIGURE 3. Lateral (A) and oblique (B) radiographs after 1.5 mo.

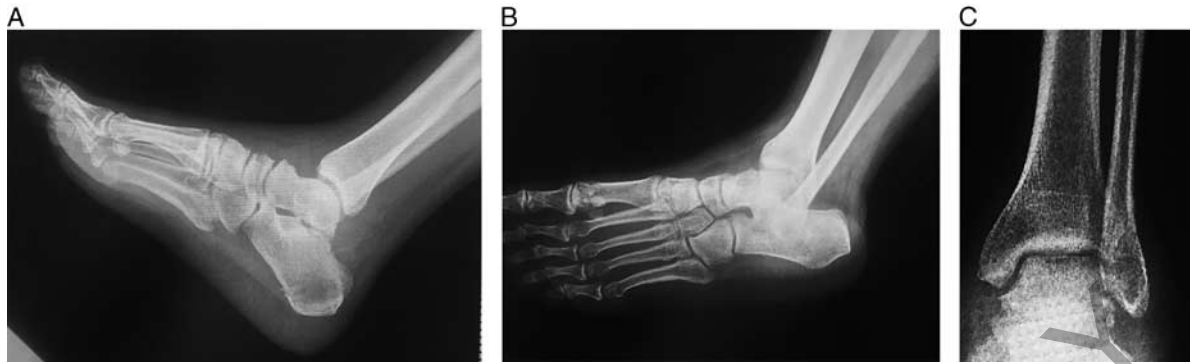


FIGURE 4. Lateral (A), oblique (B), and anteroposterior radiographs (C) at 1-year follow-up.

CONCLUSION

Talus dislocation is a rare, yet devastating, injury that may result in marked deterioration of the foot and ankle function. Open reduction may be needed because of soft-tissue entrapment. A bone distractor may help in reduction and minimize soft-tissue dissection.

REFERENCES

1. Vosoughi AR, Vallier HA. Closed pantalar dislocations: characteristics, treatment approaches, and outcomes. *J Am Acad Orthop Surg.* 2021; 29:278–287.
2. Krasin E, Goldwirth M, Otremski I. Complete open dislocation of the talus. *J Accid Emerg Med.* 2000; 17:53–54.
3. Martin R, Burdett R, Irrgang JJ, et al. Development of the foot and ankle disability index (FADI). *J Orthop Sports Phys Ther.* 1999; 29: A32–A33.
4. Weston JT, Liu X, Wandtke ME, et al. A systematic review of total dislocation of the talus. *Orthop Surg.* 2015; 7:97–101.
5. de Palma L, Santucci A, Marinelli M, et al. Clinical outcome of closed isolated subtalar dislocations. *Arch Ortho Trauma Surg.* 2008; 128: 593–598.
6. Wang HY, Wang BB, Huang M, et al. Treatment of closed subtalar joint dislocation: a case report and literature review. *Chin J Traumatol.* 2020; 23:367–371.
7. Rammelt S, Bartoníček J, Park KH. Traumatic Injury to the Subtalar Joint. *Fott Ankle Clin.* 2018; 23:353–374.