

DNA Flow Cytometry Analysis Relation to Early and Late Clinical Stages in Oral Cancer Patients

Ahmed M. Hussein¹, Mohammed G. Khalil², Ahmed O. A. Abdelrahman³, Asem M. Kamel⁴, Omar H. Soliman⁵, Omneya R. Ramadan⁶

Department of Oral and Maxillofacial Pathology, Faculty of Dentistry, Assiut University, Assiut, Egypt¹, Department of Oral Pathology, Faculty of Dentistry, Al-Azhar University (Assiut Branch), Assiut, Egypt², Department of Oral and Maxillofacial Surgery, Faculty of Dentistry, Al-Azhar University (Assiut Branch), Assiut, Egypt³, Department of Oral Medicine, Periodontology, Oral Diagnosis and Dental Radiology, Faculty of Dentistry, Al-Azhar University (Assiut Branch), Assiut, Egypt⁴, Department of Oral Medicine, Oral Diagnosis and Periodontology, Faculty of Oral and Dental Medicine, South Valley University, Qena, Egypt⁵, Department of Oral Pathology, Faculty of Dentistry, Alexandria University, Alexandria, Egypt⁶

Original Article

ABSTRACT

Introduction: Oral cancer is one of the critical global social health troubles. Lymph nodes metastasis of oral carcinomas have a significant prognosis impact. Authentic TNM staging of the neoplasms is essential to bear an assign board for disease control and prognostication. The model of grading histologically from only tissue biopsy has limitations. Abnormal DNA content has been correlated with malignant diseases. Flow cytometry can be a rapid method for quantitative test of DNA in solid tumors. Prediction the metastatic deposit in relation to the DNA flow cytometry inquiry is the point of importance.

Aim of the study: This study was operated to matched between tumor DNA content to the clinical stages of oral squamous cell carcinoma patients; to better predict the tumor behavior and to guide treatment planning.

Material and Method: A total of 40 fresh/frozen biopsies in different TNM clinical stages of oral cancer were divided into 2 groups. Group I; twenty lesions classified in stage I and stage II. Group II; twenty tumors classified as stage III and stage IV. All specimens utilized to DNA flow cytometric scanning in order to achieve the DNA ploidy and S-phase fraction.

Results: The difference in aneuploidy state and S-phase fraction between Group I, and Group II was highly statistical significant in relation to their clinical stages on the basis of clinical information and biopsy results.

Conclusions: DNA flow cytometric analysis of oral carcinomas excisions reported a significant predication to a late metastatic clinical stages of oral cancer lesions.

Key Words: DNA-Flow Cytometry, Aneuploidy, S-Phase Fraction, TNM System, Clinical Stages.

Received: 25 January 2021, **Accepted:** 19 October 2021 .

Corresponding Author: Ahmed M. Hussein, Department of Oral and Maxillofacial Pathology, Faculty of Dentistry, Assiut University, Assiut, Egypt **Tel :** 0882140591, **Mobile:** 01110100380, **E-mail:** aaattay1@gmail.com

ISSN: 2090-097X, July 2021, Vol. 12, No. 3

INTRODUCTION

Oral cancer is one of the most common malignancies and a leading cause of death in many countries. Relatively 3 to 5% of malignant lumps emanate in the oral cavity. The bulk of which match to squamous cell carcinomas (SCC^[1]). Oral malignancies have ostensibly aggressive features such as fast and endophytic development. Carcinomas histologically interact with poor differentiation, non-united mold of growth, lympho-vascular and perineural intrusion and are inclined to metastasize rapidly^[2]. Up to now, diagnosis of oral diseases is very often based on the information provided by very small excisions with histological assessment seems to be the only accepted method to definitely evaluate suspicious oral tissues. Histological diagnosis of malignant criteria shows high inter- and intra-examiner variation in grading^[3]. The expectation for patients with this pathology depends on its extent, infiltration and station, presence or

absence of metastatic transmission and to a certain degree the histopathological differentiation of the tumor^[4]. The time of choosing the therapy and estimating the expected survival is mainly based on clinico-pathological features as well as on histological grading^[5].

The disease is officially organized based on the American Joint Committee on Cancer (AJCC) TNM system. This style of clinical staging reflects the extent of cancer advancement in the whole body and is based on assessment of the size and depth of the primary lesion (T), involvement of cervical lymph nodes (N), and distant metastases (M). The TNM classification is serious to provide a structure-based allocation to adequately depict cancer prediction^[6].

Skillful staging is vital for cancer therapy selection and outcome prognosis, investigation plan, and cancer restriction activities^[7]. In early stages (T1–T2) of SCC,

which are familiar to have supportive prevision with a clinically negative neck. The public of academies achieved neck

authority based on T-stage: hold and scan policy in T1 tumors and optional neck dissection in T2 oral cancers^[8]. Approximately half rate of oral patients with SCC present with clinical category I or II disease. In recent oral carcinomas the quota of hidden metastasis is guessed at 20 and 40%. Nodal spread form the highest significant prognosticator with survival standers drop by more than 50% in N1 metastatic diseases^[9,10]. It is therefore prudent to establish the nodal status of the neck not only for prognosticating purposes, but for better imperatively for planning and giving adjuvant treatment in a proper way. The management of the clearly N0 neck has been an issue of argument^[11].

Various reading modalities including ultrasound, CT, MRI and PET scans have aimed to underpin an evidence-based approach, however large studies have demonstrated the fetters of any preoperative imaging in carefully staging the denial neck evaluation^[12]. A solution for this issue is extra specific staging of the neck to personalize operation. This indicates the need for better prognostic tools that could carefully predict the behavior of oral SCC will aid in the selection of appropriate curing strategies^[13].

Almost mortal tissues are had a diploid cell with stable chromosome sequels and a constant measure of DNA. Because chromosomal instability in solid neoplasms is indicative of diagnosis and prognosis; a number of manners are used to study the genetic and molecular abnormalities of oral cancer. The ploidy statues are commonly a sensitive and credible marker for DNA amount^[14]. DNA aneuploidy is a finger of analytical chromosomal shifts and its effects is usual a primal crucial step in carcinogenesis, and metastasis. Aneuploidy amount can be metrical by flow cytometry (FCM)^[15]. DNA-FCM was adopted as a useful capacity for catching the presence of abnormal aneuploid sublimes in preneoplastic and neoplastic tissues. The improvement of FCM test has made it feasible to measure the DNA parameters of entity cells and to quantify the ploidy stories of tumor cells. Samples for DNA-FCM measures can be prepared from tissue or cell samples so it may use a part of the excision specimens^[16].

The intent of this study were to authorized the predictive value of flow cytometric assessment of nuclear DNA amount to the early and late clinical oral cancer presentations in consecutive series of patients considered to be at higher hazard of evolve diffusion carcinoma, on the basis of specialist clinical estimation and biopsy.

MATERIALS AND METHODS

Patients Assessment

The study population consisted of 40 patients' excisions affected by SCC in the oral cavity which had been encountered in Oral Pathology Department, Faculty of

Dentistry, Alexandria University, Oral and Maxillofacial Pathology Department, Faculty of Dentistry, Assiut University, and Oral Pathology Department, Faculty of Dentistry, Al-Azhar University, Assiut Branch in the period from 2017 to 2020 (23 males and 17 females, with a mean age of 61.3 years, median age of 65 years, standard deviation 11.4, and a range of 2886-). The cases were inspected by a veteran members of the Department of Oral, Maxillofacial, and Plastic Surgery, Faculty of Dentistry, Alexandria University and the staff members of the Oral and Maxillofacial Department, Faculty of Dentistry, Al-Azhar University, Assiut Branch; to obtain the clinical data and staging. Twenty primary tumors of the study manifested in stage I and stage II with no data of any sporadic deposit; represent the Group I.

The remaining 20 cases illustrate in stage III and IV; which represent the Group II. All patients did not receive any pre-operative radiation and/or chemotherapy. The clinical presentations for the study population are shown in (Table 1). Clinical staging, pathological differentiation, and mode of infiltration of the primary carcinomas were defined according the AJCC TNM system classification of malignant neoplasms^[17]. Ethical approval for the analysis and the use of material and data without individual consent has been specifically approved by the Research Ethics Committee of Faculty of Dentistry, Assiut University.

The majority of cases in Group I were white lesions of tongue, floor of the mouth, palate, gingiva and buccal mucosa. Nine patients had other presentations or reasons for removal; ulceration in 4 cases, induration in 3, submucous fibrosis in 2. In Group II, no specific and different clinical presentation (ulceration, invasive, fungating, verruciform, papillary with red and/or white patches) was provided and biopsy was executed for purposes of possible carcinoma (Figure 1). Native lymph node metastasizes were occurred in 17 cases, and one of these malignances developed lung spread. Two samples were available from the utmost patients in the study, eight had three biopsies, five lesions had four and two had a total of sex excisions. All cases were graded on Hematoxylin and Eosin (H&E) stained sections independently by two experienced pathologists based on WHO criteria at the time of diagnosis (Figure 2), with more emphasis on architectural features than in the WHO 2005 definition^[18]. Insularity criteria were a histological non-malignant diagnosis and clinical diagnosis or suspicion of any benign lumps, patients with prior history of oral squamous carcinomas, and cases with debate in classification of their clinical stages. All cases in the study were subjected to the inclusion and exclusion criteria to avoided any selected bias. A five samples of normal oral mucosa identified in cutting taken for extraneous benign tissues

were used as a stander reference. All oral specimens within the time frame were identified for study and all demand forms and files reviewed for exclusion criteria.

Flow Cytometry Analysis

The sample that had sufficient tumor tissues from each case were included for DNA-FCM investigation. Fresh biopsies were either immediately processed or stored at -200 C for later measurements. The specimens transmitted to the Flow Cytometry Center, Department of Clinical Pathology, South Egypt Cancer Institute, Assiut University for FCM test using FACS Calibur Flow Cytometer (USA), Becton-Dickinson (B-D). Tissue fragments were submitted to mechanical disaggregation in 2 mL of detergent solution (0.1 ml citric acid, 0.5% Tween-20) [19]. The nuclei suspensions obtained were filtered over a 50 um nylon sieve, processed. The staining material operated in this examination is The Cycle TEST™ PLUS DNA Reagent Kit (BD Biosciences).

DNA Diagnostic Criteria

DNA content histogram analyses were observed according to consensus criteria [20]. The histograms that recorded less than 5000 events showed a coefficient variation (CV); ratio of standard deviation to mean of DNA state for all nuclei in the peak; higher than 10% in the G0/G1 peak, or showed an excessive amount of debris, and were classified as non-evaluable [21]. A cells were categorized diploid if only a peak (G0/G1) formed by epithelial nuclei was sitting. Aneuploid histograms were characterized by the entity of one or more extra peak(s) having addition than 10% of the epithelial nuclei outside the range of the normal diploid. The excisions with at least 2 distinct G0/G1 peaks were examined as aneuploid content. Standards DNA Index (DI) were fated as the ratio of the mean channel number of the aneuploid G0/G1 DNA peak to the total mean channel of the G0/G1 diploid peak. In fact, cells of aneuploid DNA amount were marked by single near-diploid aneuploid sublines (DI=1 and DI <1.4), whereas high aneuploid sublines (DI >=1.4) were common in neoplastic lesions. High aneuploidy tissue being characterized also by multiple DNA aneuploid sublines. The CV values of diploid G0/G1 peaks control samples were used as a mensuration of DNA resolution (ploidy accuracy): mean CV was $1.2 \pm 0.2\%$ obtained by a Gaussian curve fitting an algorithm (FloMax Software 3.0b4 2001, Partec). The S-phase fraction (SPF) is the fraction of the full cell residents that are present in the S-phase of the cell cycle and is usually asserted as a ratio. The cut off for the SPF was set as the mean ± 2 standard deviation (SD) and considered as either being low or high (Figure 3).

Data Analysis

Data collection, management, and analyses were completed using Microsoft Office Excel and the SPSS 16.0 software package (Apache Software Foundation, Chicago, Illinois). Cox regression methods were used to investigate the main independent predictors of malignant progress. Analysis of variance (ANOVA) was used to compare sex, age, location and histological differentiation whereas association among 2 variables in 2 X 2

contingency tables was evaluated with the Fisher exact test (2-sided). A P -value ≤ 0.05 was taken as statistically significant. Correlation amid conventional and novel methods for nuclear derivation was made using the Wilcoxon signed rank trial. Further, the DNA ploidy parameters were evaluated by using Cohen's kappa coefficient. P -values < 0.05 were watched as statistically important.

RESULTS

The current DNA-FCM test was used parallel to clinical data to predict the peril of metastasis in oral SCC patients. The new aids in diagnosis of the spread achieve signs to identify presence of any unknown metastatic deposit. The current subject was done on 40 fresh and frozen excisions of SCC in different clinical stages in oral cavity with variable histological grades. Hazard proportions were highly effective ($p < 0.001$) indicating the danger of a poorly differentiated carcinomas were higher than well and moderately differentiated type. High aneuploidy criterion was powerfully matched to higher stage and histopathological grade of disease whereas no serious relationship was detected with patient sex, age, and tumor location (Table 1). The normal cases were taken as standard which showed a single diploid peak (reference peak) representing G0/G1 cells (2N). They had shown no cells in the S-phase or at G2/M peak.

Of the 40 samples, 21 (52.5%) specimens were DNA aneuploid, and the last 19 neoplasms were DNA diploid. DNA aneuploidy was diagnosed mainly in 5/20 (25%) biopsies in Group I; early clinical stages, and 16/20 (80%) tumors in Group II; late clinical stages. The three quarters of Group I cases (15/20) were diploid. The DNA ploidy diagnoses are shown in the study table (Table 1). The exposure of DNA aneuploidy was 3.2 times higher in Group II than Group I. Patients with aneuploid content developed metastasis deposit rapidly than those with diploid one. The aneuploid specimens further were divided into: hyperdiploid with DI ranged from 1.12 to 1.93 with a mean of 1.56 (3 in Group II, 3 in Group I), and hypodiploid with DI ranged from 0.29 to 0.92 with a mean of 0.67 (3 in Group I, 2 in Group II). There was a highly significant association in DNA ploidy status between Group I and Group II ($p = 0.0001$). There is a minor symbolic difference in hyperdiploid cases number between Group I and Group II ($p = 0.05$). These were not statistically significantly different between the hypodiploid cases in the study groups.

The SPF values calculated for Group I ranged between 4.17% and 49.38% with a mean of 17.48%. While the SPF of the excisions in Group II ranged between 8.66% and 73.15% with a mean of 27.92%. The S-phase parameters were furthered classified into high and low SPF. High SPF reported in 18/40 patients (45%); 6 in Group I, and 12 in Group II. The remaining tissues reports low SPF 22/40

(55%); 14 in Group I, and 8 in Group II. About 30% (6/20) of biopsies in Group I had high SPF (numbers of cells in SPF were equal or higher than 17.48%), and 14/20 (70%) tumors had low SPF. In the Group II nearly 60% (12/20) of cases were high SPF (number of cells in SPF were more than 27.92%), and 8 neoplasms 40% were low. There is a relevant difference in the mean SPF ratio of Group I and Group II specimens ($p= 0.001$).

There is a high serious difference ($p < 0.0001$) between the excisions with aneuploid state and high SPF 5/20 (25%) in Group I and the same examined lesions 11/20 (55%) in Group II. This result of our research determined that the DNA-FCM test of the oral carcinoma content presented a high diagnostic indicator in anticipation the qualification of the oral cancer to produce cervical lymph node metastasis with late in the clinical stages. The aneuploidy DNA carcinomas have great ability to developed metastatic deposit even with initial clinical presentations.

So that, the FCM investigation of the oral excision may manifested a predicting aid in developing a sporadic deposit of the recent primary cancer tissues which may indicate neck lymph node dissection even in stage I or II TNM system.

In the present work, we have been able to combine results from clinical staging, histological grading, and DNA-FCM inquiry. The combination of badly differentiation, DNA aneuploidy and high SPF has increased predictive metastatic rate over both histological grading and clinical staging alone and a similar relationship holds with well and moderate differentiation grades. In opposition, the absence of poorly differentiation with diploid content showed no help to the negative predictive diffusion value. However, one of the valuable aspects of DNA test remains the ability to exclude propagation ability in low danger tumor tissues with new confidence, enabling patients to be discharged for follow up in primary care, avoiding financial cost, inconvenience and repeated biopsy.

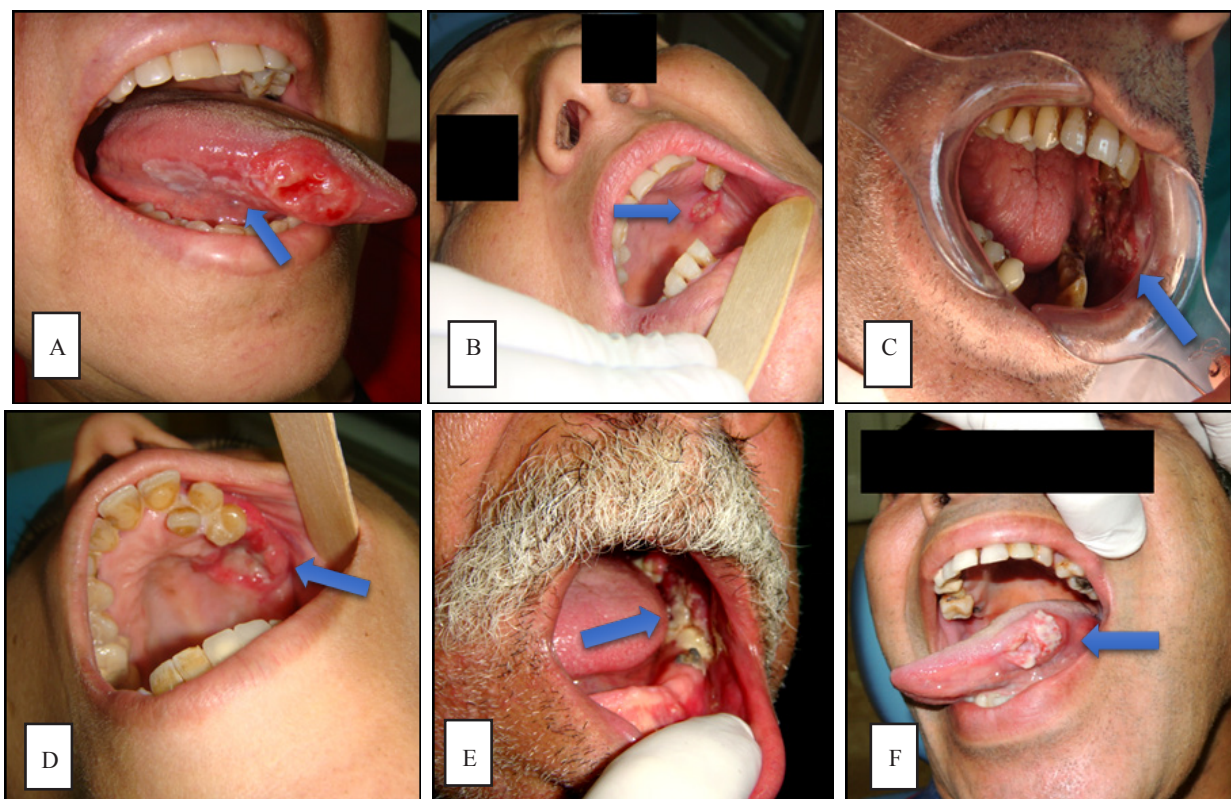


Figure 1: A Photomicrograph Showing Different Fields in Oral SCC (Blue Arrows) (A) Exophytic SCC Showing Areas of Leukoplakia involving the Right Lateral Border of the Tongue, (B) A Case of SCC Presented as a Palatal ulcer, (C) Oral SCC Presented as Endophytic Ulcer at the Buccal Mucosa Extending to the Retromolar Region, (D) Alveolar SCC of the Left Posterior Maxillary Ridge Extending to the Palate, (E) Oral SCC Exhibiting Areas of Erythroplakia and Leukoplakia in the Left Retromolar Region, (F) An Exophytic SCC of the Left Side of the Tongue Exhibiting Areas of Leukoplakia.

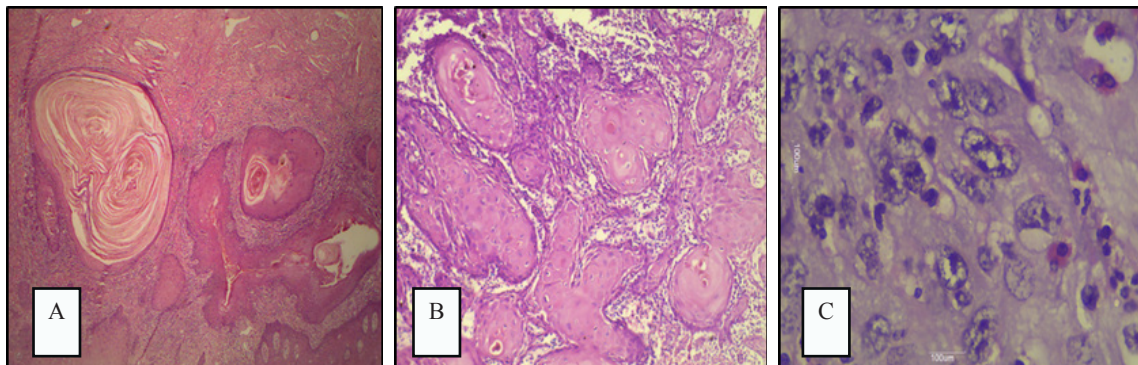


Figure 2: A Photomicrograph Showing Different Fields in Oral SCC (A) Well Differentiated OSCC at Group I (H&E X40), (B) Moderate Differentiated Oral SCC in the Form of Malignant Cell Nests at Group II (H&E X100), (C) Poorly Differentiated Oral SCC with Evident Malignant Criteria at Group II (H&E X400).

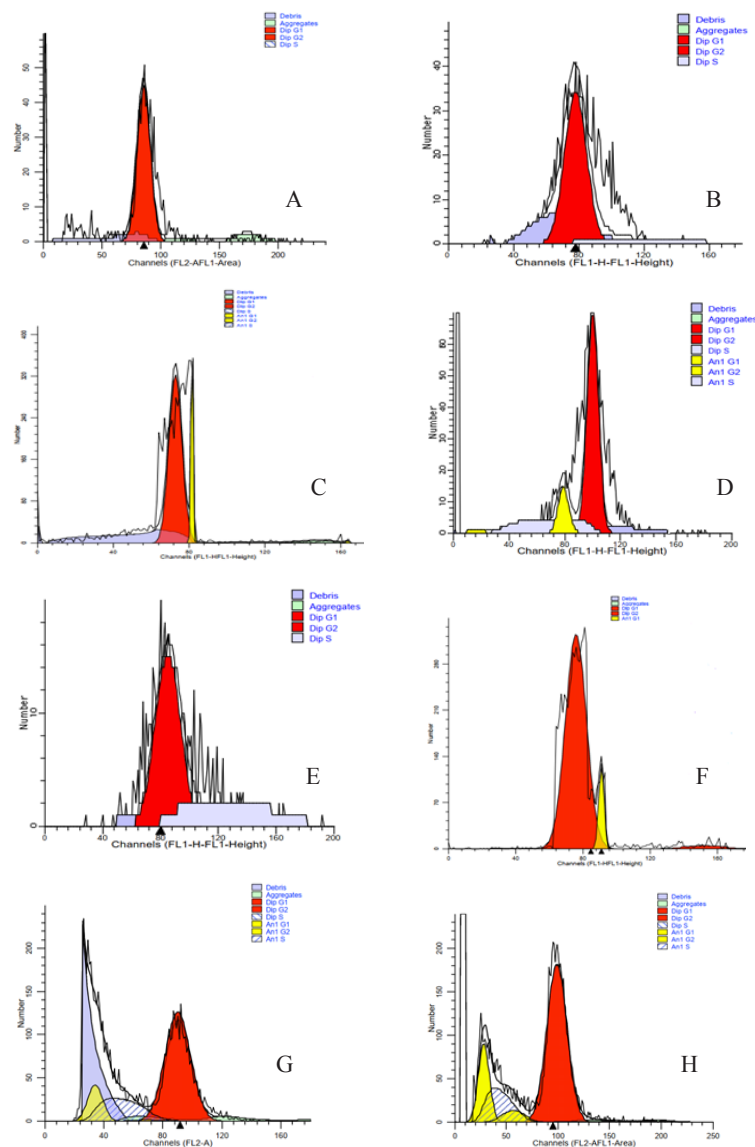


Figure 3: Different DNA Frequency Histogram Showing (A) Diploid Peak, and Low SPF (5.84%), (B) Diploid Peak, and High SPF (18.43%), (C) Aneuploid Peak, Hyperdiploid (DI= 1.12), and High SPF (19.75%), (D) Aneuploid Peak, Hypodiploid (DI= 0.53), and High SPF (22.52%), (E) Diploid Peak, and High SPF (37.26%), (F) Aneuploid Peak, Hyperdiploid (DI= 1.20), and Low SPF (8.66%), (G) Aneuploid Peak, Hypodiploid (DI= 0.38), and High SPF (62.14%), (H) Aneuploid Peak, Hypodiploid (DI= 0.29), and Low SPF (23.27%); A, B, C, and D in Group I Patients; E, F, G, and H in Cases of Group II.

Table 1: Demographic and Characteristics among Oral Cancer Patients in relation to Flow Cytometric Parameters between the Study Groups.

Group	TNM Stage	T	N	M	Sex	Age	Location					Differentiated SCC			NO	Flow cytometry					
					M/F	> 50 / ≤ 50	Tongue	Mouth F.	B. mucosa	Gingiva	Palate	M. Sinus	Well	Moderately		Poorly	DNA Polidy		SPF		
																	Diploid	Aneuploid	High	Low	
Group I	Stage 0	TIS	N0	M0	3/1	1/2	2	1	0	0	1	0	4	0	0	4	4	0	0	4	
	Stage I	T1	N0	M0	5/5	7/3	4	1	0	3	2	0	4	4	2	10	7	3	3	7	
	Stage II	T2	N0	M0	4/2	5/1	2	2	1	0	1	0	3	1	2	6	4	2	3	3	
	Group I				12/8	14/6	8	4	1	3	4	0	11	5	4	20	15	5	6	14	
	%						40%	20%	5%	15%	20%	0%	55%	25%	20%		75%	25%	30%	70%	
Group II	Stage III	T3	N0	M0	0/3	2/1	1	2	0	0	0	0	1	0	2	3	1	2	1	2	
		T1	N1	M0	2/0	1/1	0	1	0	0	1	0	0	2	0	2	0	2	0	2	
		T2	N1	M0	2/2	3/1	2	0	1	0	1	0	0	1	3	4	2	2	1	3	
		T3	N1	M0	1/1	2/0	0	1	0	1	0	0	0	0	2	2	1	1	2	0	
		T1	N2	M0	1/1	2/0	1	0	0	1	0	0	0	1	1	2	0	2	1	1	
	Stage IV	T3	N2	M0	2/0	2/0	1	0	0	0	0	1	0	0	2	2	0	2	2	0	
		T4	N0	M0	1/0	0/1	0	0	0	0	1	0	0	1	0	1	0	1	1	0	
		T4	N1	M0	1/0	1/0	1	0	0	0	0	0	0	0	1	1	0	1	1	0	
		T1	N3	M0	0/1	1/0	1	0	0	0	0	0	0	0	1	1	0	1	1	0	
		T3	N3	M0	0/1	1/0	0	0	0	1	0	0	0	0	1	1	0	1	1	0	
		T3	N2	M1	1/0	1/0	0	0	0	0	0	0	1	0	0	1	1	0	1	1	0
		Group II				11/9	16/4	7	4	1	3	3	2	1	5	14	20	4	16	12	8
		%						35%	20%	5%	15%	15%	10%	5%	25%	70%		20%	80%	60%	40%
Total				23/17	30/10	15	8	2	6	7	2	12	10	18	40	19	21	18	22		
%						37.5%	20%	5%	15%	17.5%	5%	30%	25%	45%		47.5%	52.5%	45%	55%		

DISCUSSION

One major reason for the high oral cancer burden is that almost cases present at dilatory stage [22]. Prevention of cancer spread in patients with oral SCC requires a strict assessment of the possibility of nodal advancement to target surgery appropriately. The histological grades and clinical stages is generally considered a low predictor of transformation and metastasis [23]. A state of having atypical nuclear DNA, is one of the hallmark of cancer, drives carcinogenesis and has proven ability to predict development of cancer at several body sites [24,25]. The distributions of age, gender, prevalence and grades of dysplasia, and presence of aneuploidy are comparable to other studies [24-26]. Justified on the basis of this study results, patients with higher histopathological and clinical grades (late stage) of oral carcinoma developed aneuploidy hasty. Although the hazard ratios for well and moderate histopathological and clinical grades (early stage) decreased. This in agreement with the results of Acosta *et al.* which concluded the finding of aneuploid cells is strongly indicative of malignant cells [27]. As well, Danielsen *et al.* reported that DNA ploidy study has potential as a more objective approach in cancer bumps and precancerous conditions as a result of chromosomal instability and missegregation during mitosis and has been used in a diversity of clinical settings [28].

Further, Zaini *et al.* noted that the DNA ploidy predicts cancer transformation well and combining it with dysplasia grading gave the highest predictive value [29]. In addition, Missaoui *et al.* showed in their results that DNA aneuploidy seems interesting in prognosis valuation of benign and malignant lesions in thyroid neoplasms [30]. In contrast, different studies on DNA ploidy investigation have shorting in the prediction of oral carcinogenesis and tissue transformation [25,31]; this may due to that their studies have been small series with a case-control design.

This study confirms that DNA inquiry predicts malignant growth and firmly establishes DNA ploidy analysis as a useful clinical test. This agrees with Jagric *et al.* reported that the DNA-FCM is a speed, cost-effective, and highly distinct method for sentinel lymph node metastases. But it not recommended as the only test for the detection of lymph node metastases before operations [32].

Further, the published result of Hayry *et al.* reported that the nuclear DNA ploidy of nodal tissue, mainly help as prognostic metastatic sign of oral tumors [33]. Others have found more variable results, similar studies reporting similar findings [34,35]. While others reported a lower prospect ratio [36,37], these differences probably largely accounted for by differences in study population with differing liabilities of metastasis.

In this series, poorly differentiation but not well and moderate grades was a better predictor of malignant development

by DNA-FCM aneuploidy measurement. Both absence of late clinical stage and DNA-FCM aneuploidy status had an equivalent positive and negative predictive profit, whether or not primitive spread was included in the study. This compatible by the findings presented by El-Defdar *et al.* [38]. Moreover, Oya *et al.* reported that the DNA ploidy and SPF can be tie in native progression of oral cancer [39].

This study established the value of DNA ploidy investigation in a population with an overall low incidence and opportunity of metastasis deposit without a perfect diagnosis due to lake of clinical data in fresh cancer damages. The study hypothesize that DNA ploidy test could prove to be the best predictor in developing a sporadic deposit in correlated with the clinical outcome. DNA ploidy analysis proved as effective as extension prediction, had a high negative predictive rate to exclude carcinomas with no danger of spread and was able to identify risk in tissues that appeared in premier clinical stages. However, that study had limitations. It was not possible to perform DNA ploidy inquiry on every sample, and some selection bias was likely to favor study of larger lesion with greater sample size. The research checked a few number of referred patient. The cases were included after examination by a clinician specializing and were included after referral from primary care. But the predictive value might be higher in a population that have been screened clinically and histopathology. The positive predictive worth of DNA measurement would normally be expected to rise with a higher incidence of malignant spread.

CONCLUSION

In conclusion, the results of this study provide additional evidence that DNA content analysis is a good predictor of oral cancer development assessed as having a peril of dissemination on clinical grounds. The highest predictive ratios are produced by combinations of the two techniques and the predictive values reported here exceed those from published studies to date. DNA ploidy scrutiny has profit in patient management, both to detect high danger metastatic tissues and confidently identify those with no hazard. Further studies should be showing the follow up of early clinical stages oral cancer with diploid DNA ploidy and low SPF. Manifestation of ancient metastasis lesions and its relation to their aneuploidy statuses.

FINANCIAL SUPPORT

This research did not receive any specific grant from funding agencies in the public, commercial, or not-for-profit sectors.

CONFLICT OF INTEREST

The authors declare no conflict of interest.

REFERENCES

1. Madhura MG, Rao RS, Patil S, Fageeh HN, Alhazmi A, Awan KH. Advanced diagnostic aids for oral cancer. *Dis Mon.* 2020;66(12):101034.
2. Mupparapu M, Shanti RM. Evaluation and staging of oral cancer. *Dent Clin North Am.* 2018;62(1):47-58.
3. Cheung LC, Ramadas K, Muwonge R, Katki HA, Thomas G, Graubard BI, et al. Risk-based selection of individuals for oral cancer screening. *J Clin Oncol.* 2021;JCO2002855.
4. Duprez F, Berwouts D, De Neve W, Bonte K, Boterberg T, Deron P, et al. Distant metastases in head and neck cancer. *Head Neck.* 2017;39(9):1733-43.
5. Ren J, Qi M, Yuan Y, Duan S, Tao X. Machine Learning-based MRI texture analysis to predict the histologic grade of oral squamous cell carcinoma. *AJR Am J Roentgenol.* 2020;215(5):1184-90.
6. Lydiatt WM, Patel SG, O'Sullivan B, Brandwein MS, Ridge JA, Migliacci JC, et al. Head and Neck cancers-major changes in the American Joint Committee on cancer eighth edition cancer staging manual. *CA Cancer J Clin.* 2017;67(2):122-37.
7. Huang SH, O'Sullivan B. Overview of the 8th edition TNM classification for head and neck cancer. *Curr Treat Options Oncol.* 2017;18(7):40.
8. de Bree R, van der Waal I, Doornaert P, Werner JA, Castelijns JA, Leemans CR. Indications and extent of elective neck dissection in patients with early stage oral and oropharyngeal carcinoma: nationwide survey in The Netherlands. *J Laryngol Otol.* 2009;123(8):889-98.
9. Moe J, McHugh JB, Udager AM, Braun TM, Helman JI, Ward BB. Intraoperative depth of invasion is accurate in early-stage oral cavity squamous cell carcinoma. *J Oral Maxillofac Surg.* 2019;77(8):1704-12.
10. Wirtz MM, Temming S, Kocher M, Kunze S, Semrau R. Low risk of contralateral lymph node recurrence in lateralized head and neck carcinoma after postoperative ipsilateral radiotherapy. *Strahlenther Onkol.* 2020;196(5):474-84.
11. Vassiliou LV, Acero J, Gulati A, Holzle F, Hutchison IL, Prabhu S, et al. Management of the clinically N0 neck in early-stage oral squamous cell carcinoma (OSCC). An EACMFS position paper. *J Craniomaxillofac Surg.* 2020;48(8):711-8.
12. Golusinski P, Di Maio P, Pehlivan B, Colley S, Nankivell P, Kong A, et al. Evidence for the approach to the diagnostic evaluation of squamous cell carcinoma occult primary tumors of the head and neck. *Oral Oncol.* 2019;88:145-52.
13. Almangush A, Heikkinen I, Makitie AA, Coletta RD, Laara E, Leivo I, et al. Prognostic biomarkers for oral tongue squamous cell carcinoma: a systematic review and meta-analysis. *Br J Cancer.* 2017;117(6):856-66.
14. S Papanikolaou V, Kyrodimos E, Tsiambas E, Giotakis E, Psyrri A, Ragos V, et al. Chromosomal instability in oral squamous cell carcinoma. *J BUON.* 2018;23(6):1580-2.
15. Andreou M, Vartholomatos E, Harissis H, Markopoulos GS, Alexiou GA. Past, present and future of flow cytometry in breast cancer - a systematic review. *EJIFCC.* 2019;30(4):423-37.
16. Montante S, Brinkman RR. Flow cytometry data analysis: Recent tools and algorithms. *Int J Lab Hematol.* 2019;41(1):56-62.
17. Katabi N, Lewis JS. Update from the 4th edition of the World Health Organization Classification of head and neck tumours: What is new in the 2017 WHO blue book for tumors and tumor-like lesions of the neck and lymph nodes. *Head Neck Pathol.* 2017;11(1):48-54.
18. Thompson L. World Health Organization classification of tumours: pathology and genetics of head and neck tumours. *Ear Nose Throat J.* 2006;85(2):74.
19. Frei JV, Martinez VJ. DNA flow cytometry of fresh and paraffin-embedded tissue using cytokeratin staining. *Mod Pathol.* 1993;6(5):599-605.
20. Darzynkiewicz Z, Huang X, Zhao H. Analysis of cellular DNA content by flow cytometry. *Curr Protoc Immunol.* 2017;119:5.7.1-20.
21. Chang Q, Hedley D. Emerging applications of flow cytometry in solid tumor biology. *Methods.* 2012;57(3):359-67.
22. Chakraborty D, Natarajan C, Mukherjee A. Advances in oral cancer detection. *Adv Clin Chem.* 2019;91:181-200.
23. Goodson ML, Sloan P, Robinson CM, Cocks K, Thomson PJ. Oral precursor lesions and malignant transformation-who, where, what, and when? *Br J Oral Maxillofac Surg.* 2015;53(9):831-5.
24. Thomas G, Tr S, George S P, Somanathan T, Sarojam S, Krishnankutti N, et al. Prognostic implications of DNA repair, ploidy and telomerase in the malignant transformation risk assessment of leukoplakia. *Asian Pac J Cancer Prev.* 2020;21(2):309-16.
25. Siebers TJ, Bergshoeff VE, Otte-Holler I, Kremer B, Speel EJ, van der Laak JA, et al. Chromosome instability predicts the progression of premalignant oral lesions. *Oral Oncol.* 2013;49(12):1121-8.
26. Yang X, Xiao X, Wu W, Shen X, Zhou Z, Liu W, et al. Cytological study of DNA content and nuclear morphometric analysis for aid in the diagnosis of high-grade dysplasia within oral leukoplakia. *Oral Surg Oral Med Oral Pathol Oral Radiol.* 2017;124(3):280-5.

-
27. Acosta M, Pereira J, Arroz M. Screening of carcinoma metastasis by flow cytometry: A study of 238 cases. *Cytometry B Clin Cytom.* 2016;90(3):289-94.
28. Danielsen HE, Pradhan M, Novelli M. Revisiting tumour aneuploidy - the place of ploidy assessment in the molecular era. *Nat Rev Clin Oncol.* 2016;13(5):291-304.
29. Zaini ZM, McParland H, Moller H, Husband K, Odell EW. Predicting malignant progression in clinically high-risk lesions by DNA ploidy analysis and dysplasia grading. *Sci Rep.* 2018;8(1):15874.
30. Missaoui N, Hmissa S, Mokni M, Trabelsi A, Trimech M, Lagueb I, et al. DNA content analysis in thyroid neoplasms: diagnostic and prognostic interest. *Ann Endocrinol (Paris).* 2005;66(4):333-9.
31. Bremner JF, Brakenhoff RH, Broeckaert MA, Belien JA, Leemans CR, Bloemena E, et al. Prognostic value of DNA ploidy status in patients with oral leukoplakia. *Oral Oncol.* 2011;47(10):956-60.
32. Jagric T, Mis K, Gorenjak M, Goropevsek A, Kavalar R, Mars T. Can flow cytometry reinvent the sentinel lymph node concept in gastric cancer patients? *J Surg Res.* 2018;223:46-57.
33. Hayry V, Kagedal A, Hjalmarsson E, Neves da Silva PF, Drakskog C, Margolin G, et al. Rapid nodal staging of head and neck cancer surgical specimens with flow cytometric analysis. *Br J Cancer.* 2018;118(3):421-7.
34. Kamphues C, Al-Abadi N, Bova R, Rademacher S, Al-Abadi H, Klauschen F, et al. The DNA index as a prognostic tool in hilar cholangiocarcinoma. *J Surg Oncol.* 2015;112(2):214-8.
35. Chudasama DY, Aladag Z, Felicien MI, Hall M, Beeson J, Asadi N, et al. Prognostic value of the DNA integrity index in patients with malignant lung tumors. *Oncotarget.* 2018;9(30):21281-8.
36. Reiter R, Gais P, Steuer-Vogt MK, Boulesteix AL, Deutschle T, Hampel R, et al. Centrosome abnormalities in head and neck squamous cell carcinoma (HNSCC). *Acta Otolaryngol.* 2009;129(2):205-13.
37. Zargoun IM, Bingle L, Speight PM. DNA ploidy and cell cycle protein expression in oral squamous cell carcinomas with and without lymph node metastases. *J Oral Pathol Med.* 2017;46(9):738-43.
38. El-Defdar MF, El Gerzawi SM, Abdel-Azim AA, Tohamy SM. Prognostic significance of ploidy and S-phase fraction in primary intraoral squamous cell carcinoma and their corresponding metastatic lymph nodes. *J Egypt Natl Canc Inst.* 2012;24(1):7-14.
39. Oya R, Ikemura K. Can flow cytometrically determined DNA ploidy and S-phase fraction predict regional metastasis in squamous cell carcinoma of the oral cavity? *Head Neck.* 2002;24(2):136-42.
-