

BIOLOGIC AND PROSTHETIC COMPLICATIONS WITH TWO VERSUS FOUR MINI-IMPLANTS SUPPORTING MANDIBULAR OVERDENTURES IN PATIENTS WITH KNIFE EDGE RIDGES. ONE-YEAR RESULTS OF RANDOMIZED CONTROLLED CLINICAL TRIAL

Ramy Moustafa Moustafa Ali* *and* Mohamad Hossam El-Din Helmy **

ABSTRACT

Purpose: The aim of this randomized clinical trial was to evaluate biologic and prosthetic complications with two versus four mini-implants supporting mandibular overdentures in patients with knife edge ridges.

Materials and methods: Twelve edentulous participants (6 men and 6 women, mean age =58.47 years) were randomly assigned into 2 groups; Group 1(control); included six participants who received four mini dental implants equally distributed in the interforaminal area of the mandible. Group 2 (study); included six participants who received two mini dental implants the canine area of the mandible. For both groups mandibular dentures were connected to the implants by O-ring attachments. The incidence biologic and prosthetic complications (related to the implants/ attachments and to the overdentures) were measured from base line 12 months after overdenture insertion and compared between groups.

Results: The implant survival rate, peri-implantitis, pocket depth >3mm, bone loss >1mm, separation of the metal housing from the denture base, teeth fracture, overdenture fracture, and denture relinings did not significantly differ between groups. The 4-implant group showed significant higher pain, edema, peri-implant mucositis, teeth wear, and denture border adjustments than the two implant group. The 2-implant group showed significant higher abutment bending / fracture, O/ring wear/ distortion, and O/ring damage/replacement than the 4-implant group

Conclusion: Within the limits of this short term trial, 2 mini-implants may be a suitable alternative to 4-mini-implants when used to retain mandibular overdentures as it was associated with reduced pain, edema, peri-implant mucositis, teeth wear, and denture border adjustments. However, 2-mini-implants are associated with increased prosthetic complications related to attachments as abutment bending /fracture, O/ring wear/ distortion, and O/ring damage/replacement.

* Assistant Professor, Removable Prosthodontic Department Faculty of Dentistry Fayoum University Removable Prosthodontic Department Faculty of Dentistry King of Faisal University

** Lecturer, Removable Prosthodontic Department, Faculty of Dentistry, Assiut University

INTRODUCTION

The residual ridge atrophy provides a decrease in the size of the denture-bearing areas, resulting in problems with denture stability and retention. In these situations, repeatability of occlusal contacts is difficult to obtain, and controlling the direction of occlusal forces is difficult. With horizontal displacement of the prosthesis, soft tissue irritation and rapid bone resorption may occur with resultant reduced buccolingual ridge width (knife edge ridge).¹ The use of conventional diameter implants to retain overdentures is an effective modality for edentulous patients particularly who had problems in retention and stability of mandibular conventional dentures due to mandibular bone atrophy². The high success rate of implants inserted in the interforaminal region is well documented in literature^{3,4}. Although use of only 2 implants is considered sufficient to improve denture stability, comfort, chewing efficiency and patient satisfaction^{5,6}, four implants may be recommended to support overdentures in case of high muscle attachments, easily irritable mucosa, and sharp mylohyoid ridges⁷. Zero was no significant difference in longer-term patient satisfaction, social functions and clinical and radiographic outcomes between conventional diameter two-implant-retained and four-implant-supported mandibular overdentures⁸

The amount of remaining bone in the interforaminal area usually determines the implants number and dimensions (diameter and length)⁹. In cases of reduced buccolingual ridge width (knife edge ridges), the use of conventional diameter implants may not be suitable except after massive surgical recontouring of the ridge or performing bone grafting procedures. These procedures may increase patient morbidity, costs, and treatment time^{10,11} especially in patients with chronic systemic diseases. In such cases, mini dental (single piece) implants are usually indicated to retain overdentures as they had reduced diameter (<2.8 mm) and can

be placed with flapless surgical procedures with minimal surgical interventions, thus decreasing morbidity, pain, discomfort, postoperative edema, postoperative surgical complications, and provide immediate rehabilitation of function and aesthetics on the same day of surgery¹²⁻¹⁵

In the literature, a debate usually exists regarding the number of implants needed to properly support dentures. It is usually recommended to use four mini dental implants to support the implant overdentures to compensate for reduced implant dimensions¹⁶. However, the use of four mini-implants may result in more postoperative pain and discomfort than the use of two mini-implants¹⁷. Some edentulous patients especially who had systemic diseases may reject implant the treatment because of fear of oral surgery and other psychological problems¹⁸. Furthermore, cost of the 4-mini-implants may be another limiting factor for some patients. Therefore, the use of 2 mini-implants had a clinical advantage due to the simplicity of treatment, cost effectiveness, and immediate restoration. The use of two mini-implants only to retain mandibular overdentures was documented in several studies¹⁹⁻²⁵. Two clinical studies^{24,26} concluded that marginal bone loss and implant survival rate of 2-mini dental implants retaining a mandibular overdenture is comparable to standard diameter implants. However, comparing the clinical and the prosthetic outcomes of two and four mini dental implants in randomized controlled trials was not evaluated yet.

Biologic and prosthetic complications are important factors when determining success of implant treatment as it usually guide the prosthodontist, and the patients to find the optimum treatment modality²⁷. The clinical performance of overdenture treatment usually depends on several factors such as implant number and distribution, attachment type, function load transmission to surrounding tissues, patient satisfaction with treatment, prosthetic problems and maintenance services as well as costs

(Cune, et al. 2010, Mericske-Stern, et al. 2009). Accordingly, the purpose of the present investigation was to evaluate and compare biologic and prosthetic complications with two versus four mini-implants supporting mandibular overdentures in patients with knife edge ridges. The null hypothesis was that no significant difference in biologic and the prosthetic complications between the two treatment options will be obtained.

MATERIALS AND METHODS

Patient selection and study design

Twelve edentulous participants (6 men and 6 women, mean age =58.47 years) were selected to participate in this trial from patients attending the Prosthodontic Department for follow-up after insertion of their conventional dentures. The inclusion criteria are 1) dissatisfaction with retention and stability of mandibular dentures, pain and discomfort during mastication 2) horizontal ridge atrophy with inadequate buccolingual thickness of alveolar bone (knife edge ridges) for insertion of conventional diameter implants. This was verified by making a diagnostic cone beam computerized tomography (CBCT) (fig1), 3) adequate bone height to receive implants of at least 13mm in length, with good bone quality according Lekholm and Zarb classification²⁸. The participants were excluded if they had one of the following conditions; 1) coagulation problems, 2) diseases affect the bone metabolism such as diabetes mellitus and hyperparathyroidism, 3) chemotherapy or radiation to head region in the last 2 years, 4) inadequate denture hygiene. The aim of the study was described to all participants, then informed consents were obtained. The protocol of study was approved by the review board of the ethical committee of the faculty of dentistry. A random generated number in Excel spread sheet was given to each participant and the numbers were kept in sealed envelopes. A blind dental assistant randomly

assigned the patients number into two groups using simple random method. Group 1(control); included six participants who received four mini dental implants equally distributed in the interforaminal area of the mandible. Group 2 (study); included six participants who received two mini dental implants the canine area of the mandible. For both groups mandibular dentures were connected to the implants by O-ring attachments.

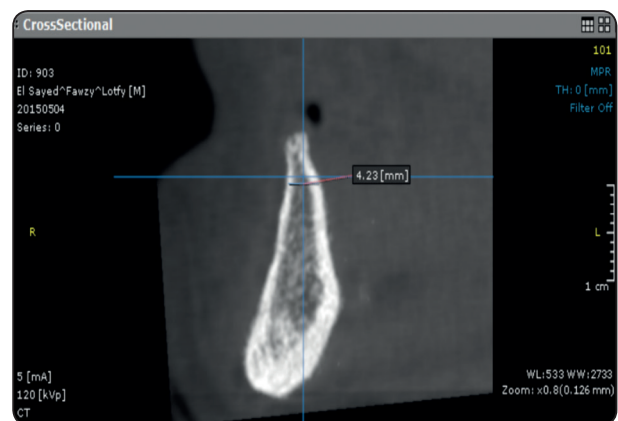


Fig. (1) Mandibular knife edge ridges (with inadequate buccolingual bone thickness)

Surgical and prosthetic interventions

New conventional maxillary and mandibular dentures were constructed to all participants using the conventional techniques. Jaw relations were recorded in centric and eccentric positions, and centric and protrusive interocclusal records were obtained. Bilateral balanced occlusal concept was constructed using semi-anatomic acrylic resin teeth. The dentures were inserted to the participants after making the necessary occlusal adjustments to ensure optimal occlusal contact in centric relation and freedom of tooth contact in lateral and protrusive excursions. The participants were instructed to wear the dentures for at least two months to promote adequate neuromuscular adaptation. Then mandibular dentures were replicated into clear acrylic resin to be used as a radiographic template. Gutta purcha markers were

attached to the template at proposed implant sites and radiographic evaluation was performed using CBCT to evaluate bone height and thickness at implant sites, and to identify proximity to vital structures. The radiographic template was then converted to surgical guide by drilling holes in the dentures corresponding between implant sites.

For both groups, the mini-implants were inserted using flapless surgical approach. Since the implants are of one-piece type, the implants were immediately loaded by overdentures after implant placement. Four mini-implants (group 1, fig 2) and two mini-implants (group 2, fig 3) (1.8 mm in diameter, 13-15mm in length, 3M ESPE, USA) were inserted parallel to each other's using the auto advance technique in lateral incisor and first premolar area (group 1) or canine areas (group 2). The surgical template was placed over the mucosa and stabilized

by hand pressure on soft tissue. Implant sites were identified in the oral mucosa using a dental probe passing through the acrylic channels of the guide to form bleeding points after removal of the guide. The implant osteotomy was prepared using initial drill (1.5mm) that continued to about 1/3 to 3/4 the implant length (according to bone density during drilling). The mini-implants was removed from the amount and inserted clockwise in the prepared implant site. After the implant has a resistance with bone, the amount was replaced with thumb wrench then torque ratchet to complete implant placement with at least 35 N/cm torque to provide initial stability required for immediate loading. The implant abutment connection (ball abutment base is oriented to be at the level of the mucosa.

For both groups, plastic tubes were snapped over the abutments to stabilize the metal housing of the

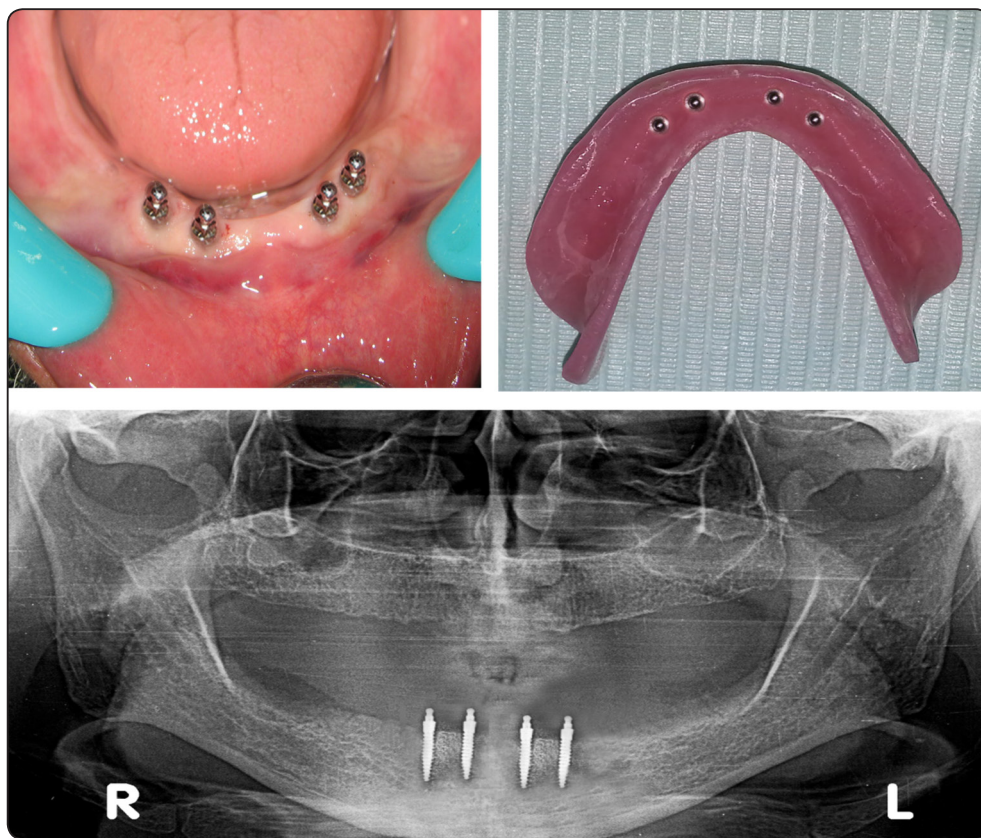


Fig. (2). Group 1 (4 mini-implants): A) intraoral view of Mini implants in place, B) O-ring attachments in the fitting surface of the overdentures, C) postoperative panoramic images

O-rings, orient the housings parallel to each other's and to prevent excess acrylic resin from escaping in the undercuts of ball abutments. The rubber O/rings were placed in the metal housings, the metal housings were snapped over ball abutments. The tissue surfaces of the mandibular dentures were relieved to create space for attachment of the metal housing, and lingual events the lingual polished surface were made to allow escapement of excess acrylic resin during the direct pickup of the housing. The metal housings were picked up to the tissue surface of the dentures using autopolymerizing acrylic resin immediately after implant insertion. Pick up was made while the patient closing in centric occlusion. The dentures were removed, excess acrylic resin was finished and the dentures were published and inserted. Adjustments of the occlusion were made to ensure freedom of contact in centric and protrusive

excursions to avoid overloading of the implants and healing period.

Postoperative medications include Antibiotics (amoxicillin 875mg + clavulanic acid 125mg, Augmentin® 1gm) were given twice daily for 5 days. Anti-inflammatory medication (ibuprofen®, 600 mg) was administered twice for 4 days postoperatively. Analgesics (Ketolac® 10mg) were given on the day of surgery and postoperatively for the first 4 days. Instruction for adequate oral hygiene and eating a soft diet were given to the participants, then follow-up visits were scheduled.

Biologic and prosthetic complications

The incidence biologic and prosthetic complications were measured from base line 12 months after overdenture insertion and compared between groups. Biologic complications (measured on

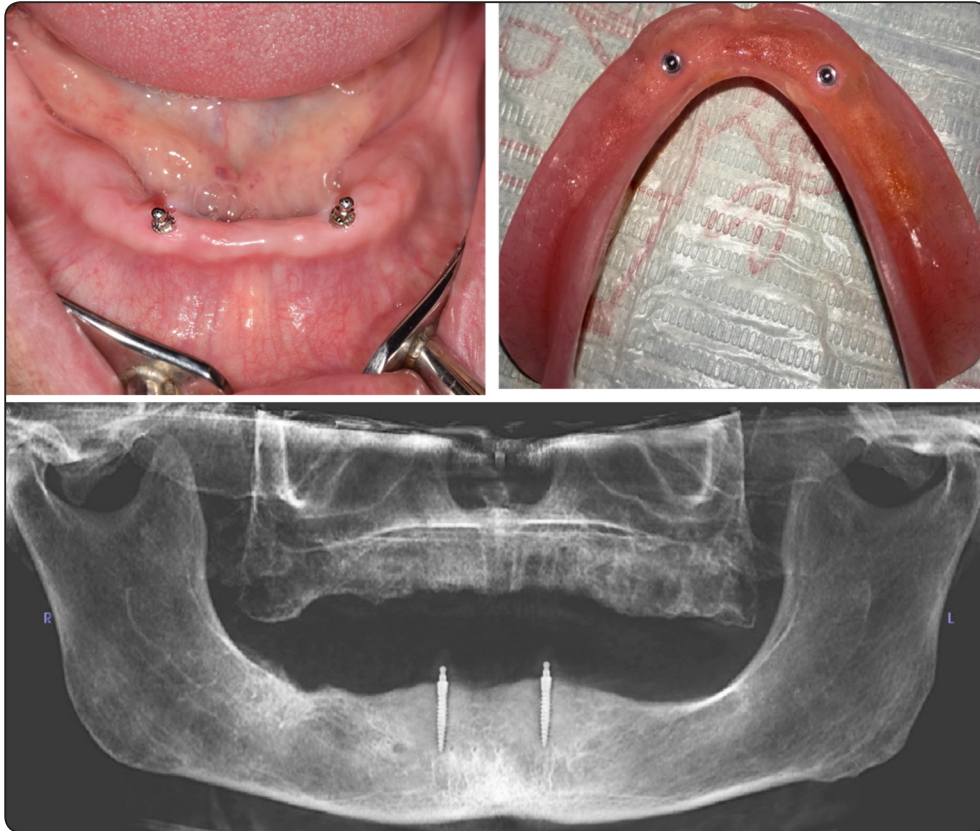


Fig. (2) Group 2 (2 mini-implants): A) intraoral view of Mini implants in place, B) O-ring attachments in the fitting surface of the overdentures, C) postoperative panoramic images

implant level) was performed according Malo et al.²⁷ and include: Implant failure, implant survival, pain, edema, suppuration, peri-implantitis, mucosal inflammation around the implants, probing depth >3 mm, and marginal bone loss > 1mm. Marginal bone level was measured on standardized digital periapical radiographs from implant abutment junction (point A) to first bone to implant contact point (A) (fig 4). Bone loss was estimated by subtraction of bone levels at follow up visits from bone level at base line.

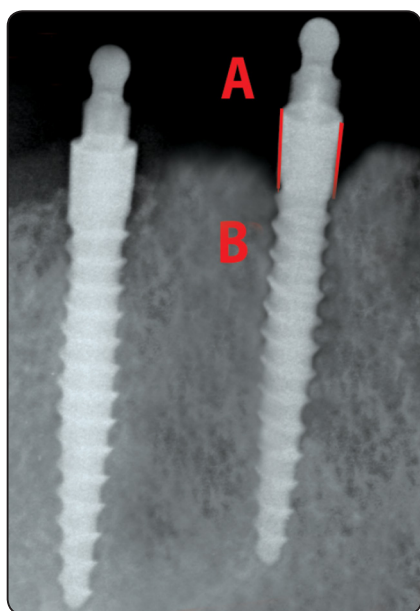


Fig. (4). Measurement of marginal bone loss on periapical radiographs.

Prosthetic complications were performed according to Naert et al.²⁹ and Elsyad et al.¹⁵ and include: 1) Complications related to the implants and attachments (measured on implant level) : implant bending/ fracture, abutment bending/ fracture, O/ring wear or distortion, O/ring damage, O/ring replacement, separation of the metal housing, fracture of the metal housing. 2) Complications related to the overdentures (measured on patient level); teeth wear, teeth fracture, overdenture fracture, adjustment of the denture borders, relining of the dentures, remaking of the dentures.

Statistical analysis

SPSS (statistical package for social science, V18, USA) was used for statistical analysis. P is significant if < 0.05 at confidence interval 95%. The incidence (frequency) and the percentage of biologic and prosthetic complications for both groups were presented using frequency distribution (contingency) tables. Comparison of biologic and prosthetic complications between groups was performed using Chi square test.

RESULTS

The incidence and percentage of biologic complications of 4-mini-implant and 2-mini-implant groups is presented in table 1. Two implants failed in each group resulting in 8.3% and 16.7% failure rate in the 4-implant and in the 2-implant group respectively. The implant survival rate was 91.7% and 83.3% for 4-implant and 2-implant group respectively. Despite the higher failure rate in the two implant group no significant difference in failure and survival rates of the implants was noted between groups. The failed implants were replaced with new implants and immediate loaded with mandibular overdentures, however, the new implants were excluded from the analysis. 8 implants (33%) in the 4 implant group was associated with pain and edema, while in the 2- implant group only one implant (8.3%) was associated with pain and edema. The 4-implant group showed significant higher pain and edema than the two implant group. Peri-implant mucositis occurred in 10 implants (41.7%) in the 4-implant group and in 2 implants (16.7%) in the 2-implant group. The 4 implant group showed significant higher peri-implant mucositis than the 2-implant group. No suppuration or bus formation occurred in both groups. Two implants (8.3%) had peri-implantitis in the 4-implant groups and one implant (8.3%) had peri-implantitis in the 2 implant group without significant difference between groups. Pocket depth >3mm occurred in 6 (25%) implants

in the 4-implant group and 4 implants (33%) in the 2-implant group. No significant difference in pocket depth between groups was noted. Marginal bone loss >1mm occurred in 5 (20.8%) implants in the 4-implant group and 5 implants (41.7%) in the 2-implant group. No significant difference in bone loss between groups was noted

Table 2. shows the incidence and percentage of prosthetic complications related to the implants and attachments of 4 mini-implant and 2- mini-implant groups (on the implant level). No implant bending/fracture or fracture of the metal housing appeared in both groups. Abutment bending /fracture occurred in 3 implants (12.5%) in 4 implant group and 5 implants (41.7%) in the 2 implant group. O/ring wear or distortion occurred in 16 implants (66.7%) in the 4 implant group and 12 implants (100%) in the 2 implant group. O/ring damage/replacement occurred in 10 implants (41.7%) in 4 implant group and 12 implants (100%) in the 2 implant group.

The 2-implant group showed significant higher abutment bending /fracture, O/ring wear/ distortion, and O/ring damage/replacement than the 4-implant group. Separation of the metal housing occurred in 4 implants (16.7%) in the 4 implant group and 1 implants (8.3%) in the 2 implant group without significant difference between groups

Table 3 represent the incidence and percentage of prosthetic complications related to the overdentures of 4 mini-implant and 2- mini-implant groups (on the patient level). 4 dentures (66.7%) in the 4-implant group and 1 denture (16.7%) in the 2-implant group we are associated with teeth wear. 4-implant group recorded significant higher teeth wear than the 2-implant group. 2 dentures (33.3%) in the 4-implant group and 1 denture (16.7%) in the 2- implant group we are associated with teeth fracture without significant difference between groups. 2 dentures (33.3%) in the 4-implant group and no dentures (0%) in the 2- implant group we

TABLE (1): Incidence and percentage of biological complications of 4 mini-implant and 2- mini-implant groups (on the implant level)

	4 mini-implants (n=24)		2-mini-implants (n=12)		P value
	Incidence	Percentage	Incidence	Percentage	
Implant failure	2	8.3%	2	16.7%	.45
Implant survival	22	91.7%	10	83.3%	.45
Pain/edema	8	33%	1	8.3%	.048*
Suppuration	0	0%	0	0%	-
Peri-implantitis	2	8.3%	1	8.3%	1.00
Mucosal inflammation (mucositis)	10	41.7%	2	16.7%	.045*
Probing depth >3 mm	6	25%	4	33%	.59
Crestal bone loss> 1mm	5	20.8%	5	41.7%	.188

*p is significant at 5%

are associated with overdenture fractures without significant difference between groups. 4 dentures (66.75) in the 4-implant group and 1 denture (16.7%) in the 2- implant group we are associated with border adjustments. 4-implant group recorded significant higher border adjustments than the

2-implant group. 3 dentures (50%) in the 4-implant group and 3 dentures (50%) in the 2- implant group we are associated with denture relining without significant difference between groups. No denture remakes were made in both groups.

TABLE (2): Incidence and percentage of prosthetic complications related to the implants and attachments of 4 mini-implant and 2- mini-implant groups (on the implant level)

	4 mini-implants (n=24)		2-mini-implants (n=12)		P value
	Incidence	Percentage	Incidence	Percentage	
Implant bending/fracture	0	0%	0	0%	-
Abutment bending/fracture	3	12.5%	5	41.7%	.040*
O/ring wear or distortion	16	66.7%	12	100%	.023*
O/ring damage/replacement	10	41.7%	12	100%	.001*
Separation of the metal housing	4	16.7%	1	8.3%	.47
Fracture of the metal housing.	0	0%	0	0%	-

*p is significant at 5%

TABLE (3): Incidence and percentage of prosthetic complications related to the overdentures of 4 mini-implant and 2- mini-implant groups (on the patient level)

	4 mini-implants (n=24)		2-mini-implants (n=12)		P value
	Incidence	Percentage	Incidence	Percentage	
Teeth wear	4	66.7%	1	16.7%	.049*
Teeth fracture	2	33.3%	1	16.7%	.56
Overdenture fracture	2	33.3%	0	0%	.21
Border adjustments	4	66.7%	1	16.7%	.049*
Relining of the dentures	3	50%	3	50%	1.00
Remaking of the dentures	0	0%	0	0%	-

*p is significant at 5%

DISCUSSION

One year follow-up period was chosen as it has been reported that major prosthetic and biologic complications occurred in the first year after insertion of the prosthesis³⁰. In this study, the 4-implant group showed higher implant failure than the 2-implant group. A similar observation was noted in another study¹⁹ in which the authors reported higher failure rates for 2- mini implants (18%) compared with 4 mini implants (11%). This could be attributed to the reduced number of implants as it reduces the total surface area of the implants with reduced bone to implant anchorage. Therefore, some mini-implant manufacturers recommends at least four in the mandible (interforaminal region), and six mini-implants in maxilla⁹. However, no significant difference in implant failure rate was noted between groups. The lack of difference in implant failure between groups was in line also with a previous study¹⁹. The 4- implant group showed significant higher incidence of pain and edema compared to two implant group. In agreement with this observation, another investigator²¹ reported that 4-mini-implants induced more intense postoperative pain compared to 2 mini implants or 2 conventional implants. This may be due to increased number of implant site preparation and proximity of implants to each other's. No suppuration occurred in both groups and no significant difference in peri-implantitis between groups was noted. This may be attributed to the flapless surgical approach used for implant placement which is usually associated with minimal wound exposure and minimal postoperative infection. The absence of suppuration means is that the implant failures occurs primary due to implant overload and implant mobility with bone resorption and without bone formation. The increased peri-implant mucositis in the 4 implant group than the 2-implant group may be attributed to the proximity of the implants to each other which facilitate plaque accumulation, complicate oral hygiene practice, and induce peri-implant mucosal inflammation. The decreased manual dex-

terity of the patient's and inability to clean the area between the implants could be responsible for this significant increase of peri-implant mucositis the four implant group. A similar observation was reported in another study²¹ which also reported that participants faced a difficulty in performing good oral hygiene in the four implant group compared to the 2 implant group.

The increased pocket depth (>3mm) occurred in 6 (25%) implants in the 4-implant group and 4 implants (33%) in the 2-implant group without difference between groups. The increased pocket depth could be attributed to the increased bone resorption around these implants and the gingival proliferation that may occur around the implants as a result of peri-implant mucosal inflammation¹³. The increased pocket depth around mini implants was in line with finding of another study³¹ which reported increased pocket depth (mean= 2.896 ± 0.140 mm) for 4-mini-implants supporting mandibular overdentures after 12 months. In this study, 41.7% of implants in the two implant group showed higher bone resorption (>1.0mm) compared to 20.8% implants in the 4-implant group, however the difference was not significant. This finding agreed with the results of a systematic review which reported that marginal bone loss values around mini-implants with below 1.5mm⁹. The increased percentage of bone loss in the two implant group was in line with another study²³ in which the authors reported higher bone loss in the 2 unsplinted mini implant group (1.40 ± 1.02 mm) compared to 2 splinted mini implant group (0.84 ± 0.66 mm) after 15-month. However, it should be noted that 10 implant in both groups was associated with bone resorption >1.5mm in the first year. This value is greater than the normal limit of bone resorption compared to standard diameter implants³². Similarly, Zweer et al, reported that narrow diameter implant we are associated with more marginal bone loss compared to regular diameter implant²⁰. This could be attributed increased loads on mini-implant compared to standard implants due

to the smaller surface area. The lack of difference in bone loss between groups could be attributed to the small sample size and the unequal implant number in groups since the statistical comparisons were performed using the percentage on the implant level. The increased bone height around mini implants was in line with finding of another study which reported increased bone loss (mean= 2.938 ± 0.176mm) for 4-mini-implants supporting mandibular overdentures after 12 months³¹.

The increased abutment bending /fracture, O/ring wear/ distortion, and O/ring damage/ replacement in the 2 implant group compared to the 4-implant group may be attributed to the increased overdenture rotation during function. This rotation occurs around the line that pass through the 2 implants with enhanced posterior ridge loading³³. Therefore, more bending moments are applied to the 2 mini-implants. Conversely, when 4 mini-implants are used, the dentures tend to settle toward the tissue rather than rotate around the implants. The overdenture rotation with 2 implants caused increased occlusal load on the implants which tend to increase abutment bending since the abutments have small diameter with decreased flexure strength. The increased load on conventional implants caused increased abutment screw loosening. Since the mini-implants are one piece, they are more liable to bending^{34, 35}. O/ring wear/ distortion, and O/ring damage/replacement occurred frequently in both groups. In line with this explanation, Elsyad et al¹⁵ reported that the most common complications was wear/ damage of O/rings and O/ring replacement. Similarly, in another study, the authors found that most frequent prosthodontic maintenance for implant overdentures was the need to change the O-ring as a result of retention loss³⁶. This occurred due to inherent problems of O/ring attachment wear and failure under occlusal loads due to friction, heat, and swelling³⁷. Moreover, friction of the O/rings with abutments during denture insertion and removal may frequently occurred especially when

implants are not parallel to each other's³⁸. This could lead to progressive loss of retention and wear and replacement of these attachment to maintain good retention levels. The increased O-ring wear and replacement in the 2 implant group compared to the 4 implant group is in line with the finding of de Souza¹⁹ after 12 months of overdenture use. Separation of the metal housing occurred in both groups without significant difference. In line with this finding other studies^{15, 39} reported detachments of the metal housings from the denture bases when mini implants were used. They added that dislodging forces during chewing and denture removal could be the reason for this separation.

The 4-implant group recorded significant higher teeth wear than the 2-implant group. This could be attributed to the increased implant support provided by increased implant number which increase chewing efficiency, muscle activity and maximum bite force resulting in more teeth wear in the 4- implant group⁴⁰. Teeth fracture occurred in both groups without significant difference. This usually occurs opposite to the attachments and may be due to separation of the artificial teeth from the denture base resulted from insufficient space for the teeth as the metal housing occupies more vertical and horizontal prosthetic space. The same reason could be responsible for fracture of the denture base opposite to the attachments which occurs due to crack initiation and propagation in the denture bases in the area of the attachments⁴¹. This crack is resulted from stress concentration in the thin layer of acrylic resin around the housing⁴². The fracture of the denture bases with the use of mini implants we reported also in other studies^{15, 39, 43}. 4-implant group recorded significant higher border adjustments than the 2-implant group. The increased implant number resulted in an increase in overdenture stability and retention. This stabilize the denture base in position and provide limited path of insertion and removal. Consequently, the denture borders may interfere with the ridge undercuts and usually needs relief

and adjustments to avoid pain, ulceration and discomfort compared to the two implant group. Denture relining occurred in both groups without significant difference between groups. The increased denture relining as a prosthetic complication with the use of mini implants was in agreement with the finding of other studies^{15,39,43}. The increased denture relining may be due to the fact that overdentures are mainly tissue supported and mini implants are used to provide retention and stability with minimal implant support as an occlusal space existed between the O-ring and the implant ball head³⁹. This space together with increased masticatory efficiency may be responsible for increased loading on the residual ridges and consequently bone resorption increases and denture relining is increased.

The limitation of this study included the small patient number, and the short evaluation period. Future randomized controlled trials are needed to ensure the finding of this study on long term.

CONCLUSION

Within the limits of this short term trial, 2 mini-implants may be a suitable alternative to 4-mini-implants when used to retain mandibular overdentures as it was associated with reduced pain, edema, peri-implant mucositis, teeth wear, and denture border adjustments. However, 2-mini-implants are associated with increased prosthetic complications related to attachments as abutment bending /fracture, O/ring wear/ distortion, and O/ring damage/replacement.

REFERENCES

1. Turk PE, Geckili O, Turk Y, Gunay V, Bilgin T. In vitro comparison of the retentive properties of ball and locator attachments for implant overdentures. *Int J Oral Maxillofac Implants* 2014; 29: 1106-1113.
2. Mericske-Stern RD, Taylor TD, Belser U. Management of the edentulous patient. *Clin Oral Implants Res* 2000; 11 Suppl 1: 108-125.
3. Batenburg RH, Meijer HJ, Raghoobar GM, Van Oort RP, Boering G. Mandibular overdentures supported by two Branemark, IMZ or ITI implants. A prospective comparative preliminary study: one-year results. *Clin Oral Implants Res* 1998; 9: 374-383.
4. Davis DM, Rogers JO, Packer ME. The extent of maintenance required by implant-retained mandibular overdentures: a 3-year report. *Int J Oral Maxillofac Implants* 1996; 11: 767-774.
5. Feine JS, Carlsson GE, Awad MA, Chehade A, Duncan WJ, Gizani S, Head T, Lund JP, MacEntee M, Mericske-Stern R, Mojon P, Morais J, Naert I, Payne AG, Penrod J, Stoker GT, Jr., Tawse-Smith A, Taylor TD, Thomason JM, Thomson WM, Wismeijer D. The McGill Consensus Statement on Overdentures. Montreal, Quebec, Canada. May 24-25, 2002. *Int J Prosthodont* 2002; 15: 413-414.
6. Thomason JM, Feine J, Exley C, Moynihan P, Muller F, Naert I, Ellis JS, Barclay C, Butterworth C, Scott B, Lynch C, Stewardson D, Smith P, Welfare R, Hyde P, McAndrew R, Fenlon M, Barclay S, Barker D. Mandibular two implant-supported overdentures as the first choice standard of care for edentulous patients--the York Consensus Statement. *Br Dent J* 2009; 207: 185-186.
7. Walton JN, MacEntee MI. A retrospective study on the maintenance and repair of implant-supported prostheses. *Int J Prosthodont* 1993; 6: 451-455.
8. Meijer HJ, Raghoobar GM, Batenburg RH, Visser A, Vissink A. Mandibular overdentures supported by two or four endosseous implants: a 10-year clinical trial. *Clin Oral Implants Res* 2009; 20: 722-728.
9. Lemos CA, Verri FR, Batista VE, Junior JF, Mello CC, Pellizzer EP. Complete overdentures retained by mini implants: A systematic review. *J Dent* 2017; 57: 4-13.
10. Stellingsma C, Vissink A, Meijer HJ, Kuiper C, Raghoobar GM. Implantology and the severely resorbed edentulous mandible. *Crit Rev Oral Biol Med* 2004; 15: 240-248.
11. Stellingsma K, Raghoobar GM, Meijer HJ, Stegenga B. The extremely resorbed mandible: a comparative prospective study of 2-year results with 3 treatment strategies. *Int J Oral Maxillofac Implants* 2004; 19: 563-577.
12. LaBarre EE, Ahlstrom RH, Noble WH. Narrow diameter implants for mandibular denture retention. *J Calif Dent Assoc* 2008; 36: 283-286.

13. Elsyad MA, Gebreel AA, Fouad MM, Elshoukoui AH. The clinical and radiographic outcome of immediately loaded mini implants supporting a mandibular overdenture. A 3-year prospective study. *J Oral Rehabil* 2011; 38: 827-834.
14. Elsyad MA, Ghoneem NE, El-Sharkawy H. Marginal bone loss around unsplinted mini-implants supporting maxillary overdentures: a preliminary comparative study between partial and full palatal coverage. *Quintessence Int* 2013; 44: 45-52.
15. Elsyad MA. Patient satisfaction and prosthetic aspects with mini-implants retained mandibular overdentures. A 5-year prospective study. *Clin Oral Implants Res* 2016; 27: 926-933.
16. Bidra AS, Almas K. Mini implants for definitive prosthodontic treatment: a systematic review. *J Prosthet Dent* 2013; 109: 156-164.
17. Guo Y, Kono K, Suzuki Y, Ohkubo C, Zeng JY, Zhang J. Influence of marginal bone resorption on two mini implant-retained mandibular overdenture: An in vitro study. *J Adv Prosthodont* 2021; 13: 55-64.
18. Assuncao WG, Zardo GG, Delben JA, Barao VA. Comparing the efficacy of mandibular implant-retained overdentures and conventional dentures among elderly edentulous patients: satisfaction and quality of life. *Gerodontology* 2007; 24: 235-238.
19. de Souza RF, Ribeiro AB, Della Vecchia MP, Costa L, Cunha TR, Reis AC, Albuquerque RF, Jr. Mini vs. Standard Implants for Mandibular Overdentures: A Randomized Trial. *J Dent Res* 2015; 94: 1376-1384.
20. Zweers J, van Doornik A, Hogendorf EA, Quirynen M, Van der Weijden GA. Clinical and radiographic evaluation of narrow- vs. regular-diameter dental implants: a 3-year follow-up. A retrospective study. *Clin Oral Implants Res* 2015; 26: 149-156.
21. Ribeiro AB, Della Vecchia MP, Cunha TR, Sorgini DB, Dos Reis AC, Muglia VA, de Albuquerque RF, Jr., de Souza RF. Short-term post-operative pain and discomfort following insertion of mini-implants for retaining mandibular overdentures: a randomized controlled trial. *J Oral Rehabil* 2015; 42: 605-614.
22. Jofre J, Cendoya P, Munoz P. Effect of splinting mini-implants on marginal bone loss: a biomechanical model and clinical randomized study with mandibular overdentures. *Int J Oral Maxillofac Implants* 2010; 25: 1137-1144.
23. Jofre J, Hamada T, Nishimura M, Klattenhoff C. The effect of maximum bite force on marginal bone loss of mini-implants supporting a mandibular overdenture: a randomized controlled trial. *Clin Oral Implants Res* 2010; 21: 243-249.
24. Jawad S, Barclay C, Whittaker W, Tickle M, Walsh T. A pilot randomised controlled trial evaluating mini and conventional implant retained dentures on the function and quality of life of patients with an edentulous mandible. *BMC Oral Health* 2017; 17: 53.
25. Valente MLC, Bolfarini C, de Oliveira DP, Dos Reis AC. Dental mini-implant designs to support overdentures: Development, biomechanical evaluation, and 3D digital image correlation. *J Prosthet Dent* 2021.
26. Aunmeungtong W, Kumchai T, Strietzel FP, Reichart PA, Khongkhunthian P. Comparative Clinical Study of Conventional Dental Implants and Mini Dental Implants for Mandibular Overdentures: A Randomized Clinical Trial. *Clin Implant Dent Relat Res* 2017; 19: 328-340.
27. Maló P, de Araújo Nobre M, Lopes A, Ferro A, Botto J. The All-on-4 treatment concept for the rehabilitation of the completely edentulous mandible: A longitudinal study with 10 to 18 years of follow-up. *Clin Implant Dent Relat Res* 2019.
28. Lekholm U, Zarb G. Patient selection and preparation. In: Branemark PI, Zarb G, Albrektsson T, eds. *Tissue integrated prosthesis: osseointegration in clinical dentistry*. Chicago. Quintessence Publishing Co. Inc. 1985: 199-209.
29. Naert I, Alsaadi G, Quirynen M. Prosthetic aspects and patient satisfaction with two-implant-retained mandibular overdentures: a 10-year randomized clinical study. *Int J Prosthodont* 2004; 17: 401-410.
30. MacEntee MI, Walton JN, Glick N. A clinical trial of patient satisfaction and prosthodontic needs with ball and bar attachments for implant-retained complete overdentures: three-year results. *J Prosthet Dent* 2005; 93: 28-37.
31. Omran M, Abdelhamid A, Elkarargy A., Sallom M. Mini-Implant Overdenture Versus Conventional Implant Overdenture (A Radiographic and Clinical Assessments). 2013; 9: 89-97.
32. Lekholm U, Adell R, Lindhe J, Branemark PI, Eriksson B, Rockler B, Lindvall AM, Yoneyama T. Marginal tissue reactions at osseointegrated titanium fixtures. (II) A cross-sectional retrospective study. *Int J Oral Maxillofac Surg* 1986; 15: 53-61.

33. van Steenberghe D, Quirynen M, Naert I, Maffei G, Jacobs R. Marginal bone loss around implants retaining hinging mandibular overdentures, at 4-, 8- and 12-years follow-up. *J Clin Periodontol* 2001; 28: 628-633.
34. Shatkin TE, Shatkin S, Oppenheimer AJ. Mini dental implants for the general dentist: a novel technical approach for small-diameter implant placement. *Compendium* 2003; 24: 26-34.
35. Preoteasa E, Melescanu-Imre M, Preoteasa CT, Marin M, Lerner H. Aspects of oral morphology as decision factors in mini-implant supported overdenture. *Rom J Morphol Embryol* 2010; 51: 309-314.
36. Park JH, Shin SW, Lee JY. Bar versus ball attachments for maxillary four-implant retained overdentures: A randomized controlled trial. *Clin Oral Implants Res* 2019; 30: 1076-1084.
37. Branchi R, Vangi D, Virga A, Guertin G, Fazi G. Resistance to wear of four matrices with ball attachments for implant overdentures: a fatigue study. *J Prosthodont* 2010; 19: 614-619.
38. Dantas Ide S, Souza MB, Morais MH, Carreiro Ada F, Barbosa GA. Success and survival rates of mandibular overdentures supported by two or four implants: a systematic review. *Braz Oral Res* 2014; 28: 74-80.
39. Preoteasa E, Imre M, Preoteasa CT. A 3-year follow-up study of overdentures retained by mini-dental implants. *Int J Oral Maxillofac Implants* 2014; 29: 1170-1176.
40. Elsyad MA, Hegazy SA, Hammouda NI, Al-Tonbary GY, Habib AA. Chewing efficiency and electromyographic activity of masseter muscle with three designs of implant-supported mandibular overdentures. A cross-over study. *Clin Oral Implants Res* 2014; 25: 742-748.
41. Elsyad MA, Errabti HM, Mustafa AZ. Mandibular Denture Base Deformation with Locator and Ball Attachments of Implant-Retained Overdentures. *J Prosthodont* 2016; 25: 656-664.
42. Darbar UR, Huggett R, Harrison A. Stress analysis techniques in complete dentures. *J Dent* 1994; 22: 259-264.
43. Scepanovic M, Calvo-Guirado JL, Markovic A, Delgado-Ruiz R, Todorovic A, Milicic B, Mistic T. A 1-year prospective cohort study on mandibular overdentures retained by mini dental implants. *Eur J Oral Implantol* 2012; 5: 367-379.