

Subtotal pancreatectomy in risky patients with periampullary cancers: new surgical center experience

Bashir A. Fadel^a, Tameem Ibraheem^a, Magdy M. Mahdy^c, Khaled S. Mohamed^c, Sahar M. Hassany^b

^aUnit of Hepatobiliary Surgery, Department of General Surgery, ^bDepartment of Tropical Medicine and Gastroenterology, Al Rajhi Liver University Hospital, Faculty of Medicine, ^cDepartment of Anesthesia and Intensive Care, Assiut University, Assiut, Egypt

Correspondence to Dr. Sahar M. Hassany, MD, Department of Tropical Medicine and Gastroenterology, 7th Floor, Alrajhi University Hospitals, Assiut 71111, Egypt.
Mob: 01007314122;
E-mail: saharhassany@yahoo.com

Received: 17 February 2020

Revised: 7 March 2020

Accepted: 20 March 2020

Published: 28 August 2020

The Egyptian Journal of Surgery 2020, 39:677–681

Background

The pancreatic leak is the most dangerous complication postpancreaticoduodenectomy. There are many risk factors for the development of pancreatic fistula (PF) such as texture of the pancreas and its duct size.

The aim was to decrease the incidence of PF in these risky patients.

Patients and methods

A retrospective study was performed on 20 periampullary tumors patients treated by subtotal pancreatectomy between April 2015 and September 2017, which were performed in Assiut Al Rajhi Liver Hospital. Subtotal pancreatectomy was performed in patients with soft pancreas which could not hold stitches and small duct size of less than 3 mm. Also, the authors follow the results of postoperative pancreatic leakage, other morbidity and mortality.

Results

A PF type A developed in three cases and did not require any further management, one case developed PF type B who also developed delayed gastric emptying and improved after 3 months; one case of abdominal abscess was managed by insertion of pig tail; two cases of wound infection improved by repeated dressing; the mean hospital stay was 7 days except for the patient who developed PF type B and delayed gastric emptying whose hospital stay was prolonged to 1 month; the mortality rate was one case, who was a female patient of 70 years old and died by myocardial infarction 1 week postoperatively.

Conclusion

Subtotal pancreatectomy with stapling can be done safely in risky patients to decrease the incidence of PF, but further large randomized trials are needed.

Keywords:

pancreatic fistula, periampullary tumors, subtotal pancreatectomy

Egyptian J Surgery 39:677–681

© 2020 The Egyptian Journal of Surgery
1110-1121

Introduction

Pancreaticoduodenectomy (PD) is a complicated surgical procedure. The best results and outcomes have been demonstrated at high-volume centers [1,2]. In experienced surgeons, the median operative time for the Whipple procedure is 5.5 h, with a median blood loss of 350 ml and mortality of less than 4% [3].

A pancreatic fistula (PF) occurs due to disruption of pancreatic ducts and leakage of pancreatic fluid following pancreatic resection.

Postoperative pancreatic fistula (POPF) is diagnosed when the amylase from the pancreatic drain on or after postoperative day 3 is greater than three times the upper limit of the normal serum amylase content, according to the International Study Group on Pancreatic Fistulas [4,5]. Clinically relevant POPFs (grade B or C) occur in ~5–10% of patients, although in some series the incidence is as high as 22% [6,7]. PFs can lead to sepsis and hemorrhage if they are not

adequately drained externally. These complications are associated with a mortality of 20–40%, prolonged hospitalization, and increased hospital expenses [6].

The risk of developing POPF is increased with various factors, such as obesity, preoperative bilirubin level, as well as a soft pancreas and a narrow duct size. Other factors that have also contributed to increased risk of POPF include drain amylase greater than 4000 U/l on postoperative day 1, significant blood loss, and prolonged operative time [6,8–10]. In one study, a risk score, calculated using only BMI and pancreatic duct width on preoperative computed tomography imaging, accurately predicted the risk of POPF [11].

This is an open access journal, and articles are distributed under the terms of the Creative Commons Attribution-NonCommercial-ShareAlike 4.0 License, which allows others to remix, tweak, and build upon the work non-commercially, as long as appropriate credit is given and the new creations are licensed under the identical terms.

In a study of 2752 patients under pancreatic resection, 256 (9.3%) patients developed a clinically relevant POPF (International Study Group on Pancreatic Fistulas grade B or C) [12]. Detection of microorganisms in the POPF was associated with a higher rate of post-pancreatectomy hemorrhage (42 vs 22%), sepsis (38 vs 7%), wound infection (30 vs 7%), reoperation (48 vs 11%), and overall 90-day mortality (20 vs 4%), and length of hospital stay (median 42 vs 26 days). An infected POPF was identified as an independent risk factor for sepsis, wound infection, and reoperation by multivariate analysis. However, it is unclear how this increased risk for complications can be best mitigated (e.g. by earlier antibiotic therapy, or by procedural or surgical intervention).

Prevention of POPF using various techniques for handling the pancreatic stump or anastomosis, prophylactic somatostatin and its analogs, and prophylactic pancreatic duct stenting has been attempted with varying success.

Patients and methods

A retrospective study was performed on 20 patients treated for periampullary tumors by subtotal pancreatectomy between April 2015 and September 2017 were done in Assiut Al Rajhi Liver Hospital. Ethical approval was taken from the faculty of Medicine ethical committee, Assiut University. All cases were performed by two surgeons only.

Preoperative assessment of tumor was detected by multislice computed tomography abdomen and patient fitness for the operation. Confirmation of tumor respectability, texture of the pancreas, and pancreatic duct size were obtained intraoperatively.

Operative technique

All surgeries were performed under balanced general anesthesia with intraoperative monitoring for vital signs, and patient-controlled analgesia with opioids was the method chosen for postoperative analgesia.

Bilateral subcostal incision was done and then exploration of the abdomen to exclude distant metastasis. Separation of the gastrocolic ligament was achieved by the LigaSure device and complete mobilization of the right colon till the cecum, and then full Kocherization of the duodenum until the left renal vein will be achieved. The aortocaval lymph node will be assessed if metastasis was suspected and will be

sent for frozen section to take the decision and if positive the procedure will be aborted. Dissection of the lower border of the pancreas was done to expose the superior mesenteric vein (SMV) and creation of the tunnel between the neck of the pancreas and the PV.

Dissection of the gall bladder from the liver bed and ligation of the cystic duct and cystic artery were done. common bile duct (CBD) is dissected and is cut above the level of cystic duct and its distal part will be ligated to protect against the spillage of the tumor.

Dissection of the common hepatic artery (CHA) and lymphadenectomy with porta hepatis lymphadenectomy was performed. Ligation of the gastro duodenal artery (GDA) and right gastric artery, skeletonization of the portal vein, and the HA proper were done. Confirmation of the tunnel between the neck of the pancreas and PV was detected. The duodenal bulb is cut and the pylorus is preserved; marginal stitches were taken from both sides of the pancreatic body and by cutting the head of the pancreas with a safety margin.

A cut is made 15 cm from the jejunum away from the duodenojejunal flexure followed by dissection of this part until complete dissection of the ligament of Treitz.

Dissection of the specimen from the portal vein and removal of the mesopancreas with the specimen was done. The pancreatic stump was to be assessed for its consistency, duct size, and to assess whether it could hold stitches or not.

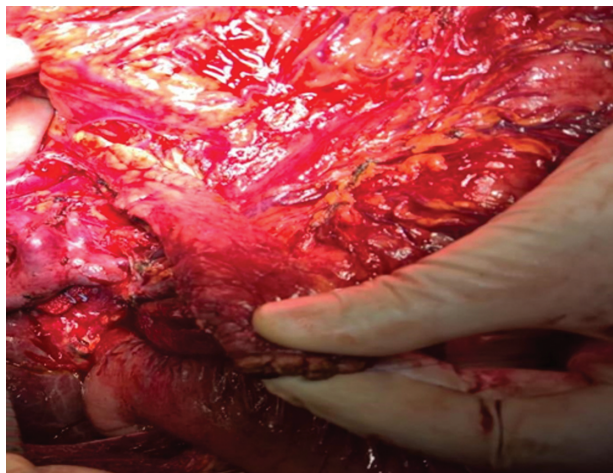
If the pancreatic stump was soft with small duct size and could not hold stitches, the decision would be subtotal pancreatectomy.

Complete mobilization of the pancreatic stump from the mesocolon and the splenic vessels up to 5 cm from the hilum of the spleen up to 70% of the pancreas was done. Using a linear stapler (Fig. 1), the mobilized part is cut with occlusion of the pancreatic duct by a linear stapler . . . we close the jaw of the stapler gradually in 2 min and we fire it slowly in 1 min (Fig. 2).

Hepaticojejunostomy and duodenojejunostomy were done. To confirm the hemostasis, three drains were to be inserted: subhepatic, pancreatic, and pelvic. Closure of the abdomen was by the PDS loop.

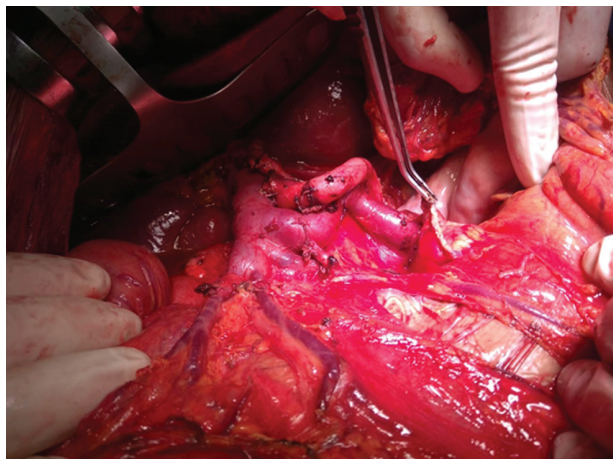
PF is defined according to an international study group of PF by measurements of amylase in drainage fluid [13].

Figure 1



Mobilized pancreatic stump.

Figure 2



Pancreatic remnant stump after stapler resection.

According to the type of PF conservative management was the first line.

Both exocrine and endocrine pancreatic functions were followed up after surgery by testing the level of blood sugar every 2 months and 3-days fecal fat was calculated in cases with severe diarrhea. Although there was no severe form of diarrhea we did the test two times and stop it as prophylactic pancreatic enzymes were taken by the patients.

Other postoperative morbidities as delayed gastric emptying, bile leakage, intra-abdominal collections, and wound infection were followed.

Mortality rates in the hospital stay or within 30 days of the operation were detected.

Table 1 Demographic data of the studied patients

Age (years)	
Mean	60
Range	41–70
Sex [n (%)]	
Male	8 (40)
Female	12 (60)
Pathology [n (%)]	
Pancreatic adenocarcinoma	8 (40)
Ampullary adenocarcinoma	4 (20)
Cholangiocarcinoma	5 (25)
Duodenal adenocarcinoma	3 (15)

Table 2 Postoperative complications

Pancreatic fistula	4 (three grade A—one grade B)
Delayed gastric emptying	1
Endocrine insufficiency	0
Exocrine insufficiency (severe form)	0
Intra-abdominal collection (abscess)	1
Bile leakage, bleeding	0
Cardiovascular complications	1
Wound infection	2

Results

Twenty patients were included in this study; patient characteristics are reported in Table 1.

In all patients, the texture of the pancreas was soft and could not hold stitches with duct size of less than 3 mm.

Postoperative complications are summarized in Table 2.

A grade A PF developed in three (15%) cases which did not require further management. A grade B PF developed in one patient and was managed conservatively; the same patient also developed delayed gastric emptying which presented by loss of appetite which led to decreased body weight and improved after 3 months. One case developed abdominal abscess 7×7 cm peripancreatic and was managed conservatively by insertion of pig tail drainage under sonographic guide. Two cases developed wound infection which was improved by repeated dressing.

Four cases were diabetic preoperative, three of them were controlled by oral hypoglycemic and one case was controlled by insulin. Their diabetes mellitus (DM) was not worsening up to 1 year follow-up postoperatively.

Exocrine pancreatic insufficiency is diagnosed in most of the patients with chronic diarrhea/steatorrhea and chronic abdominal pain; doing 3 days stool fat was calculated in two cases with mild form of diarrhea.

The mortality rate was one case who was a female patient of 70 years old who died from myocardial infarction 1 week postoperatively.

The mean hospital stay was 7 days, except for a patient who developed PF grade B and delayed gastric emptying whose hospital stay was prolonged by 1 month.

Discussion

The improvement of diagnostic tools and surgical experience reflected in the management of periampullary tumors. The mortality rates are decreased to less than 5% in specialized centers but the morbidity rates are still high [14,15]. The PF is one of the most severe complications post-PD, which may lead to several complications such as hemorrhage, septic complications, intra-abdominal collection, re-laparotomy, and prolonged hospital stay [16].

As pancreaticoenteric anastomosis is the Achilles' heel of PD due to the activation of pancreatic enzymes by enteric secretions so that the risk of PF is hazardous [17,18]. There are different techniques to avoid pancreatic leakage from pancreaticoenteric anastomosis but unfortunately with no uniform results [19]. As in the literature, the predicable risk factors of pancreatic leakage are texture of the pancreas (soft and friable) and pancreatic duct size (<3 mm) [13], our interesting approach in risky patients depends on the fact that it is possible to remove up to 70% of the pancreas without the development of endocrine abnormalities (subtotal pancreatectomy) [20], after Whipple's resection if the pancreas was soft and could not hold stitches. Moreover if the pancreatic size did not exceed 3 mm we proceeded to subtotal pancreatectomy and occlusion of the pancreatic duct by a linear stapler.

As pancreaticoenteric anastomosis was avoided, complications of PF were reduced as the activation of pancreatic enzymes would not occur [21]. Also as the size of the remnant pancreas was decreased, the incidence of PF was reduced [22].

In this approach, complications of total pancreatectomy were avoided. DM in these cases is

reportedly brittle and difficult to control; also exocrine deficiency will be developed [23,24].

In comparison with Tabatabei and colleagues pancreaticojejunostomy was done [23]. The incidence of fistula is much better in our study, so the overall morbidity and mortality are better. In comparison with other studies of subtotal pancreatectomy [25,26], there are no difference in early or late results of morbidity and mortality.

In this approach, the risk of PF was reduced. Endocrine complications were not present as in Maqnússon *et al.* [26] who reported that there was improvement of glucose tolerance after subtotal pancreatectomy. In most of the cases included in the study exocrine abnormalities in the form of diarrhea or abdominal pain was present and were treated accordingly without severe course. Also, the hospital stay was shortened except in one case, so it was advantageous as the patients would need adjuvant chemotherapy; they would receive it in the proper time.

Some authors concluded that subtotal pancreatectomy with stapling is a safe alternative technique in risky patients, which avoids the hazards of PF and decreases its incidence post-PD operation [13].

Conclusion

Subtotal pancreatectomy with stapling is a safe, less complicated, and time-saving approach in risky patients without affecting the oncological principles or long-term survival.

Postoperatively DM does not worsen, and prophylactic enzymes and multivitamins are recommended for patients to control exocrine pancreatic insufficiency.

Many researches on a large number of patients are needed for support this technique.

Financial support and sponsorship

Nil.

Conflicts of interest

There are no conflicts of interest.

References

- 1 Birkmeyer JD, Sun Y, Wong SL, Stukel TA. Hospital volume and late survival after cancer surgery. *Ann Surg* 2007; 245:777.
- 2 Fong Y, Gonen M, Rubin D, Radzyner M, Brennan MF. Long-term survival is superior after resection for cancer in high-volume centers. *Ann Surg* 2005; 242:540.

- 3 Cameron JL, Riall TS, Coleman J, Belcher KA. One thousand consecutive pancreaticoduodenectomies. *Ann Surg* 2006; 244:10.
- 4 Butturini G, Daskalaki D, Molinari E, Scopelliti F, Casarotto A, Bassi C. Pancreatic fistula: definition and current problems. *J Hepatobiliary Pancreat Surg* 2008; 15:247.
- 5 Bassi C, Dervenis C, Butturini G, Fingerhut A, Yeo C, Izbicki J, *et al.* Postoperative pancreatic fistula: an international study group (ISGPF) definition. *Surgery* 2005; 138:8.
- 6 Lai EC, Lau SH, Lau WY. Measures to prevent pancreatic fistula after pancreatoduodenectomy: a comprehensive review. *Arch Surg* 2009; 144:1074.
- 7 Cullen JJ, Sarr MG, Ilstrup DM. Pancreatic anastomotic leak after pancreaticoduodenectomy: incidence, significance, and management. *Am J Surg* 1994; 168:295.
- 8 El Nakeeb A, Salah T, Sultan A, El Hemaly M, Askr W, Ezzat H, *et al.* Pancreatic anastomotic leakage after pancreaticoduodenectomy. Risk factors, clinical predictors, and management (single center experience). *World J Surg* 2013; 37:1405.
- 9 Graham JA, Kayser R, Smirniotopoulos J, *et al.* Probability prediction of a postoperative pancreatic fistula after a pancreaticoduodenectomy allows for more transparency with patients and can facilitate management of expectations. *J Surg Oncol* 2013; 108:137.
- 10 Yeh TS, Jan YY, Jeng LB, *et al.* Pancreaticojejunal anastomotic leak after pancreaticoduodenectomy – multivariate analysis of perioperative risk factors. *J Surg Res* 1997; 67:119.
- 11 Roberts KJ, Sutcliffe RP, Marudanayagam R, *et al.* Scoring system to predict pancreatic fistula after pancreaticoduodenectomy: a UK multicenter study. *Ann Surg* 2015; 261:1191.
- 12 Loos M, Strobel O, Legominski M, *et al.* Postoperative pancreatic fistula: microbial growth determines outcome. *Surgery* 2018; 164:1185.
- 13 Müller MW, Friess H, Kleeff J, *et al.* Is there still a role for total pancreatectomy?. *Ann Surg* 2007; 246:966–974.
- 14 Büchler MW, Wagner M, Schmied BM, Uhl W, Friess H, Z'Graggen K. Changes in morbidity after pancreatic resection: toward the end of completion pancreatectomy. *Arch Surg* 2003; 138:1310–1314.
- 15 Büchler MW, Friess H, Wagner M, Kulli C, Wagener V, Z'Graggen K. Pancreatic fistula after pancreatic head resection. *Br J Surg* 2000; 87:883–889.
- 16 Batignani G, Fratini G, Zuckermann M, Bianchini E, Tonelli F. Comparison of Wirsung-jejunal duct-to-mucosa and dunking technique for pancreatojejunostomy after pancreatoduodenectomy. *Hepatobiliary Pancreat Dis Int* 2005; 4:450–455.
- 17 Daskalaki D, Butturini G, Molinari E, Crippa S, Pederzoli P, Bassi C. A grading system can predict clinical and economic outcomes of pancreatic fistula after pancreaticoduodenectomy: results in 755 consecutive patients. *Langenbeck's Arch Surg* 2011; 396:91–98.
- 18 Fernández-Cruz L, Belli A, Acosta M, Chavarria EJ, Adelsdorfer W, López-Boado MA, *et al.* Which is the best technique for pancreatocenteric reconstruction after pancreaticoduodenectomy? A critical analysis. *Surg Today* 2011; 41:761–766.
- 19 You D, Jung K, Lee H, Heo J, Choi S, Choi D. Comparison of different pancreatic anastomosis techniques using the definitions of the international study group of pancreatic surgery: a single surgeon's experience. *Pancreas* 2009; 38:896–902.
- 20 Marcus SG, Cohen H, Ranson JHC, *et al.* Optimal management of the pancreatic remnant after pancreaticoduodenectomy. *Ann Surg* 1995; 221:635–648.
- 21 Ahrin B, Tranberg KG, Andrin-Sandberg A, Bengmark S. Subtotal pancreatectomy for cancer: closure of the pancreatic remnant with staplers. *AHPB Surg* 1990; 2:29–39.
- 22 Balzano G, Pecorelli N, Piemonti L, Ariotti R, Carvello M, Nano R, *et al.* Relaparotomy for a pancreatic fistula after a pancreaticoduodenectomy: a comparison of different surgical strategies. *HPB (Oxford)* 2014; 16:40–45.
- 23 Maeda H, Hanazaki K. Pancreatogenic diabetes after pancreatic resection. *Pancreatol* 2011; 11:268–276.
- 24 Tabatabaei SA, Hashemi SM. Pancreatic anastomosis leakage management following pancreaticoduodenectomy how could be manage the anastomosis leakage after pancreaticoduodenectomy. *J Res Med Sci* 2015; 20:161–164.
- 25 Gall FP. Subtotal duodenopancreatectomy of the head of the pancreas. Preliminary report of an alternative operation to total pancreatectomy. *Eur J Surg Oncol* 1988; 14:387–392.
- 26 Magnússon J, Bengmark S, Tranberg KG. Reduced insulin secretion by subtotal pancreatectomy: preservation of insulin sensitivity and glucose tolerance in postoperative patients. *Scand J Gastroenterol* 1990; 25:669–675.