

Radomized Clinical Trial

Efficacy of Genicular Nerve Radiofrequency Ablation Versus Intra-Articular Platelet Rich Plasma in Chronic Knee Osteoarthritis: A Single-Blind Randomized Clinical Trial

Abdelraheem Elawamy, MD¹, Emad Zariief Kamel, MD¹, Safaa A. Mahran, MD²,
Hebatallah Abdellatif, MD³, Manal Hassanien, MD²

From: ¹Intensive Care and Pain Management Department, Assiut University, Assiut, Egypt; ²Rheumatology and Rehabilitation Department, Faculty of Medicine, Assiut University, Assiut, Egypt; ³Aswan University, Aswan, Egypt

Address Correspondence:
Emad Zariief Kamel, MD
Department of Anesthesia, Assiut University Hospital
Assiut, Egypt 74111
Email: emadzariief@yahoo.com

Disclaimer: There was no external funding in the preparation of this manuscript.

Conflict of interest: Each author certifies that he or she, or a member of his or her immediate family, has no commercial association (i.e., consultancies, stock ownership, equity interest, patent/licensing arrangements, etc.) that might pose a conflict of interest in connection with the submitted manuscript.

Manuscript received: 06-02-2020
Revised manuscript received: 06-24-2020
Accepted for publication: 08-03-2020

Free full manuscript:
www.painphysicianjournal.com

Background: Chronic knee osteoarthritis is a common problem with increasing of the aging population. Pulsed radiofrequency and intraarticular platelet rich plasma injection are well evidenced beneficial modalities for pain alleviation in such groups of patients.

Objective: The primary goal in this study was to compare the 2 modalities regarding pain alleviation evaluated by visual analog scale. The secondary goal focused upon the change of the Index of Severity for Osteoarthritis of the Knee by Lequesne.

Study Design: Single-blind randomized interventional clinical trial.

Setting: University hospitals.

Methods: Two hundred patients with chronic knee osteoarthritis were equally and randomly distributed into 2 groups. Group PRF received pulsed radiofrequency, whereas the group PRP received intraarticular platelet-rich plasma. The visual analog scale and index of severity of osteoarthritis were evaluated before intervention, after one week (for visual analog scale only), then after 3, 6, and 12 months.

Results: Visual analog scale was significantly lower in the PRF group compared to the PRP group at 6 and 12 months with *P*-values of 0.01 and 0.04, respectively. Regarding to the postinterventional index of severity of osteoarthritis, it was significantly lower in the PRF group than the PRP group with *P*-values of 0.001 at 3, 6, and 12 months follow-up.

Limitations: Physical and analgesic therapy were not included in data collection, and there was no control group.

Conclusion: Pulsed radiofrequency of the genicular nerves can be considered superior to knee intraarticular platelet-rich plasma injection for sustained pain relief and the lower severity index in patients with chronic knee osteoarthritis.

Key words: Pulsed radio frequency, platelet-rich plasma, chronic knee osteoarthritis, chronic pain

Pain Physician 2021; 24:

Chronic osteoarthritis (OA) is not uncommon in people over the age of 45. OA affects physical activity mainly through pain which leads to fatigue and limitation of joint function. Economic burdens include increased health care utilization and impaired quality of

life (1,2). Nowadays, with the increased life expectancy and body mass index, the impact of OA is expected to rise (3,4). The most common joint affected by OA is the knee, with a higher incidence in women especially those over the age of 55 (5-7).

Non-surgical treatment modalities of knee osteoarthritis (KOA) commonly include physical therapy and rehabilitation, nonsteroidal anti-inflammatory medications (NSAIDs), and intraarticular steroid or visco-supplement injections. Although conservative management is commonly effective, such modalities may not be effective in a small percentage of KOA patients, and some of them develop serious adverse effects (8). Intraarticular steroid injection is not devoid from complications, e.g. deterioration of the articular cartilage, crystal-induced synovitis, fat necrosis, tissue atrophy, hematoma, vascular necrosis, and sepsis (9). Intraarticular hyaluronic acid also has some conflicting results (10).

One of the attractive modalities is pulsed radiofrequency (PRF), which induces ablation of the genicular nerves and is very beneficial in some scenarios unresponsive to medical therapies and not amenable for total knee replacement therapy. Radiofrequency can optimally and safely alleviate pain and decrease the joint stiffness (11). Intraarticular platelet-rich plasma (PRP) is another promising option for chronic KOA and can alleviate pain over a few months after injection (12).

To our knowledge, this is the first study to compare the effectiveness of such 2 modalities: PRF of the

genicular nerves versus intraarticular PRP injection in chronic KOA upon pain and joint disability with one-year follow-up.

Primary Outcome: The pain relief of the involved joint as evaluated by the visual analog scale (VAS).

Secondary Outcome: The improvement of Index of Severity for Osteoarthritis of the Knee (ISK) (13) and the incidence of complications related to each intervention within the follow-up period.

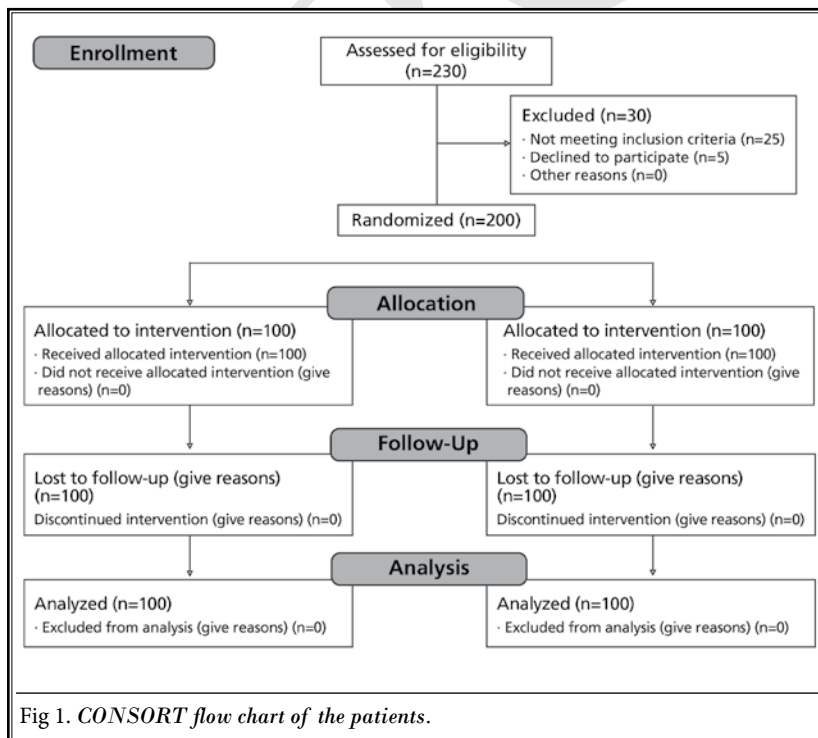
METHODS

Two-hundred patients with chronic KOA were recruited in this randomized single-blind interventional clinical trial. Patients were presented at the outpatient clinic of the rheumatology and rehabilitation department and chronic pain clinics of the anesthesia department.

The study has been approved by the local institutional ethics review board of the Faculty of Medicine and registered in clinical trials with the identification number of NCT03886142. Written informed consent was obtained from every participant. The work has followed the Good Clinical Practice and carried out in accordance with the Declaration of Helsinki (14) and the CONSORT Statement for Reporting Trials as shown in Fig. 1.

The inclusion criteria included chronic KOA with pain of at least 3 months duration refractory to conservative management, e.g., physiotherapy and analgesics. Radiological inclusion criteria included advanced osteoarthritis of the knee (Grade III – IV) according to the Kellgren-Lawrence Grading Scale (15). Exclusion criteria included acute knee pain (< 3 months), connective tissue diseases affecting the knee, serious neurological or psychiatric disorders, history of intraarticular injections therapy within the past 3 months, sciatic pain, knee surgery, and current use of an anticoagulant.

The recruited patients were randomly and equally assigned to 2 groups: Group PRF received ultrasound guided genicular nerve radiofrequency ablation and group PRP received ultrasound guided intraarticular platelet rich plasma



injection. Group distribution was accomplished using a computer-generated randomization schedule. On the day of the procedure, the physician reviewed the electronic medical records and confirmed which procedure was to be used for the patient.

Physicians who performed the follow-up assessment were kept blind to the groups. All procedures were performed in the operating room.

Ultrasound-Guided Genicular Nerve Radiofrequency Ablation (Group PRF)

The patient was positioned supine on the operating table with a pillow under the popliteal fossa to reduce discomfort. Initially, sterile preparation of the operative field and sterile cover wrapping of the MyLab 7 (Esaote, Europe B.V. Maastricht, Netherlands) 10-19 MHz high frequency linear transducer was done. A dedicated pre-programmed protocol for optimization of the parameters (depth, focal zone, frequency, and color Doppler settings for low-flow vessels) was used. The transducer was first placed on the junctions between the epicondyle and shaft of the femur and tibia. The transducer was then moved up or down to identify the genicular arteries which were usually seen near the periosteal areas as confirmed by color Doppler ultrasound (16).

Given that the superior lateral (SL), superior medial (SM), and inferior medial (IM) genicular arteries travel along each genicular nerve, the location of the needle tip was within the vicinity of each genicular artery. After identifying the genicular arteries, the skin and subcutaneous tissue were anesthetized with 1 mL of 1% lidocaine at each target point. The needle was inserted using the long-axis view of the ultrasound probe. After positioning the needle tip next to a genicular artery, a 10 cm 22-gauge radiofrequency (RF) cannula with 5 mm active tip (NeuroTherm™, Medpoint GmbH, Hamburg, Germany) was inserted. The cannula was advanced percutaneously. To reach the desired distance between the cannula tip and the desired nerve, the cannula tip was manipulated until sensory stimulation was elicited at 0.6 V, 50 Hz, meaning that the distance between the active tip and the genicular nerve was at least 0.3 cm. To avoid inadvertent motor nerves ablation, the nerve was checked for the absence of fasciculation on its corresponding area of the lower limb with a current of 2.0 V at 2 Hz. A volume of 2 mL lidocaine 2% was injected before the start of the RF; after one minute, pulsed RF at 42°C was performed for 120 seconds in 3 cycles (17).

Thereafter, the same procedure was administered

to other genicular nerves, respectively. The patients were discharged and instructed to rest for 24 hours with the use of topical ice. Paracetamol supplementation was allowed if they experienced pain in the treated region. Participants were advised to mobilize on the next day whenever they feel comfortable.

Ultrasound-Guided PRP injection (Group PRP)

The PRP samples were prepared in the Hemostasis Laboratory of Assiut university hospital after instructing the patients not to administer drugs such as NSAIDs, anticoagulants, and corticosteroids at least 24 hours before the procedure; they were instructed to drink plenty of water the day before the procedure and avoid food for 4 hours before blood collection.

PRP preparation: Aspiration of blood (30 mL) from the median cubital vein with a specific needle (22-gauge, one-inch needle) was used for the preparation of PRP (5 to 6 mL). Baseline platelet count of each patient was obtained, and the sample was not used if produced at a concentration < 300% of such value. Under complete aseptic conditions, the procedure was done at 22 to 26°C, and the blood was collected in centrifuge test tubes then labeled with identification data (name and age). The sample was mixed gently with an anticoagulant (acid citrate dextrose) in a ratio of 10:1.5, then distributed into 15 tubes (2 mL for each). The tubes were then sent for the first centrifugation for separation (rate of 3500 rpm, over 10 minutes). When the blood was separated into an upper red blood cells (RBC) layer and plasma-buffy coat, the plasma was withdrawn into another sterile tube and underwent the second centrifugation for activation of the platelets (rate of 4000 rpm, over 7 minutes). Platelets were finally settled down as PRP; the upper 3/4th supernatant was removed and the lower PRP (4 to 5 mL) was obtained. The PRP sample was then activated just before its injection by the addition of 10% calcium chloride in a ratio of 1:10 and agitation through vigorous shaking. The final volume was 4 to 5 mL of PRP collected into a sterile syringe to be ready for intraarticular injection (18).

After administration of local anesthesia and placement of MyLab 7 (Esaote, Europe B.V. Maastricht, Netherlands) 10-19 MHz high frequency linear transducer with a dedicated pre-programmed protocol for optimization of the parameters visualization (depth, focal zone, frequency, and color Doppler settings for low-flow vessels at the top of the patella), the intraarticular injection was administered under sterile conditions. A 50 mm long 22-gauge needle (Visioplex

needle, Vygon Company, France) was inserted into the knee joint at the upper outer quadrant of the patella via the in-plane technique; then, the prepared PRP solution was injected into the knee joint space. Patients remained under medical care for an hour and were then discharged if no complications were detected. The same procedure was repeated one month later for all patients. In case of the presence of postprocedural pain, paracetamol was prescribed.

Data Collection

All baseline values of the next parameters were assessed prior to the procedure and recorded. Pain intensity was assessed by the 10-point visual analog scale (VAS) in which 0 = no pain and 10 = worst pain perceivable (1 ry {sp?} outcome). The VAS measurements were evaluated by the end of 1 week, and 3, 6, and 12 months. The ISK (13) was also evaluated by the end of 3, 6, and 12 months. To obtain valid baseline values and outcome measurements, all patients were instructed on how to appropriately fill out the VAS and ISK prior to the procedure. Patient's satisfaction was assessed by Likert's scale (19); grade 1 (satisfaction of 30%), grade 2 (satisfaction of 30% to 50%), grade 3 (satisfaction of 50% to 80%),

and grade 4 (satisfaction above 80%). Both grades 3 and 4 were classified as "overall satisfied."

All adverse events, including numbness, paresthesia, neuralgia, and motor weakness, were documented. Paracetamol was allowed during the next month only, then ibuprofen full dose was allowed later if needed.

Statistical Analysis

Based upon our retrospective records (such data were not included in the study) of chronic KOA pain alleviation by intraarticular injection of PRP, we have found that by 5 to 7 months, the mean VAS raised to a value of 5 ± 2.5 (mean \pm standard deviation). This study has assumed that the PRF can reduce such value by at least 20%. A sample size of 91 patients per group was considered to attain a study power of 80% and detect a difference at the significance level of 5% of the VAS, so we have enrolled 100 patients in each group for compensation of any drop out. Data were first analyzed for parametricity by the Kolmogorov-Smirnova test. Data analysis within the same group was done by Wilcoxon Signed Ranks test (non-parametric data) and paired T-test (parametric data). Comparison between groups was done by the Mann-Whitney test (non-parametric data) and unpaired T-test (parametric data). Statistical analysis was done using the computer program IBM, SPSS (Statistical Package for Social Sciences), Version 23, 2015. We have considered a P value < 0.05 to be statistically significant.

RESULTS

The 200 participants in the 2 study groups have non-significant differences regarding their demographic data, disease duration and course, radiographic Kellgren-Lawrence Grading Scale, other clinical data, and erythrocyte sedimentation rate as shown in Table 1.

The pain VAS scale showed significant difference between the 2 groups at 6 and 12 months. Within each group, there was a significant decrease during the whole study period in the PRF group, while in the PRP group, there was a significant decrease until 6 months only (Fig. 2).

The ISK was significantly lower in the PRF group than the PRP group over the whole follow-up period. The ISK also showed a significant decrease in comparison to the basal pre-interventional value in both groups during the whole study duration (Fig. 3). Both groups showed overall satisfaction during the first 6 months after interventions with insignificant differences between the 2 groups. At 12 months, the PRP group had

Table 1. Demographic and clinical data.

Variables	Group PRF (n=100)	Group PRP (n=100)	P value
Gender male/female	50/50	49/51	0.88
Age (years)	47.78 \pm 6.9	48.45 \pm 7.7	0.57
Disease duration (years) \pm SE	7.9 \pm 0.48	8.79 \pm 0.48	0.52
Kellgren-Lawrence Grading Scale			
Mean \pm SD	3.89 \pm 0.32	3.88 \pm 0.4	0.84
Median (interquartile range)	4(0)	4(0)	
Course			
Stationary	52%	52%	0.97
Progressive	27%	28%	
Regressive	21%	20%	
Varus knee deformity	87%	88%	0.83
Myalgia	55%	57%	0.78
Juxta articular osteoporosis	32%	29%	0.64
Erosions	64%	60%	0.56
Use of NSAID	57%	52%	0.48
ESR SE	38.08 \pm 1.73	38.1 \pm 1.67	0.99

Data are presented as ratio, mean \pm standard deviation (SD) or standard error (SE), or percentage. ESR erythrocyte sedimentation rate. $P < 0.05$ is considered statistically significant.

a significantly lower satisfaction value than the PRF group (Table 2).

Only 2 patients in the PRF group experienced pain at the site of the injection and received paracetamol with resolution by the first week, and one patient in the PRP group had joint effusion which responded to ice packs and paracetamol.

DISCUSSION

In the present study, we have investigated the difference between the effect of ultrasound-guided genicular nerve PRF ablation versus intraarticular PRP injection on OA related knee pain VAS scale and ISK throughout a follow-up period of 12 months. To our knowledge, this is the first study comparing the 2 modalities. We have found that the improvement of VAS was significant and satisfactory in both groups specially in the first 3 months. Patients who received PRF experienced sustained pain relief during the whole follow-up period in comparison to the those in the PRP group where pain relief was maintained for the first 6 months only.

PRF is an alternating current that generates a thermal lesion on the target tissue (terminal sensory nerve endings); its use is increasingly directed to treat many chronic painful conditions like KOA (20). Our results regarding PRF agree with Choi et al (21) who investigated the effectiveness and safety of fluoroscopically guided radiofrequency neurotomy in patients with chronic KOA. Their patients who underwent radiofrequency neurotomy showed a significant decrease in pain VAS scale over a follow-up period of 12 months, and the authors denoted safety of the procedure.

Similar results were reported by Kesikburun et al (11) who had also performed ultrasonography guided genicular nerve PRF on 29 patients with chronic KOA, and they found 50% reduction of pain VAS with $P < 0.01$; the Western Ontario McMaster Universities (WOMAC) index throughout 3 months was improved with $P < 0.01$.

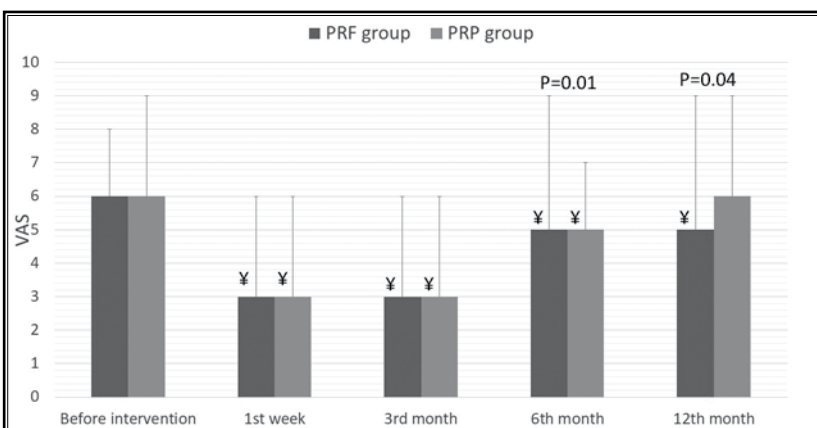


Fig 2. Pain visual analog scale during the study period. Data are presented as median (interquartile range). $P < 0.05$ is considered statistically significant. (¥) significant difference in comparison to the baseline value within the same group.

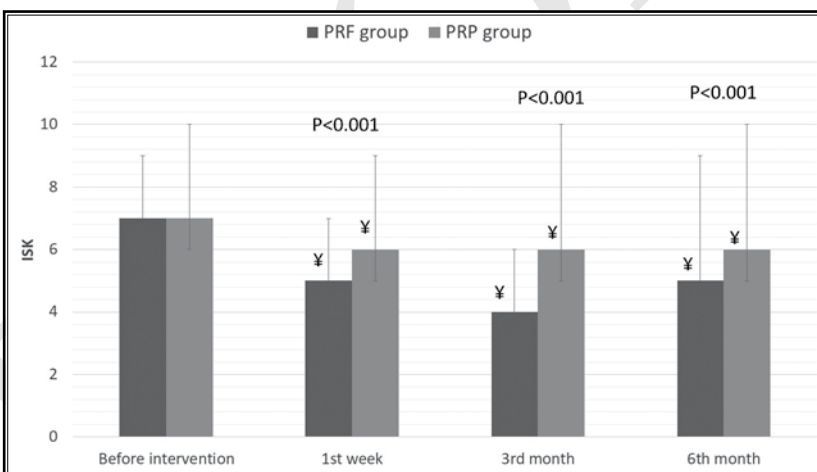


Fig 3. Index of Severity for Osteoarthritis of the Knee by Lequesne during the study period. Data are presented as median (interquartile range). $P < 0.05$ is considered statistically significant. (¥) significant difference in comparison to the baseline value within the same group.

Table 2. Likert's satisfaction of the patients.

Variables	Group PRF (n = 100)	Group PRP (n = 100)	P value
After 3 months	4 (1)	3 (1)	0.1
After 6 months	3 (0)	3 (0)	0.26
After 12 months	3 (0)	2 (0)	< 0.001

Data are presented as median value. $P < 0.05$ is considered as statistically significant.

Arif and Arora's study (22) investigated the efficacy of PRF on the 4 genicular nerves and mentioned that the technique is a minimally invasive procedure; it can be

considered as a good alternative to total knee replacement. They mentioned that genicular nerve PRF can reduce pain up to more than 6 months duration. On the other hand, Hong et al (23) performed a systematic review and meta-analysis of 12 randomized controlled trials to evaluate the efficacy of RF treatment on knee pain and function. The meta-analysis concluded that RF can significantly reduce the pain; however, rarely improves joint function. They reported that RF ablation of genicular nerves has a relatively long-lasting analgesic effect.

In our study we have performed PRF under ultrasound guidance, which has been reported to be safer and superior to the traditional fluoroscopic guided procedure especially in the presence of anatomic variations of the genicular nerves. Previous studies mentioned that direct visualization of the needle position and trajectory using the ultrasound can guarantee a successful PRF because of proper localization of the injected nerve. In addition, ultrasound is considered portable and affordable and does not expose the patient or investigator to radiation (11,24,25).

We preferred to use PRF treatment rather than traditional RF ablation. In PRF treatment, the target tissue temperature is often kept at 42°C, so that nerve destruction and the associated problems such as neuropathic pain or Charcot joints are not expected. Moreover, the PRF procedure appears to be safer than RF ablation in terms of neuritis-like reactions and motor deficits and conserving both motor and autonomic nerve fibers (26). Our rationale behind targeting 3 genicular nerves (SM, IM, and SL) was based upon their proximity to the same named genicular arteries. The IL nerve, which lies very near to the neck of fibula, was not targeted to avoid the possibility of the common peroneal nerve injury (16).

Franco et al (27) revealed a lack of consensus on the number and origin of nerve branches innervating the anterior knee capsule. All dissections revealed the following 6 nerves: superolateral branch from the vastus lateralis, superomedial branch from the vastus medialis, middle branch from the vastus intermedius, inferolateral (recurrent) branch from the common peroneal nerve, inferomedial branch from the saphenous nerve, and a lateral articular nerve branch from the common peroneal nerve. Nerve branches showed variable proximal trajectories but constant distal points of contact with femur and tibia. The inferolateral peroneal nerve branch was found to be too close to the common peroneal nerve, making it inappropriate

for RF neurotomy (27). Kesikburun et al (17) reported significant pain relief and functional improvement in severe to moderate degenerative KOA after PRF procedure. However, they mentioned that the PRF procedure had not included SM and IM genicular nerves.

In the other hand, PRP carries dual effects upon the joint's cartilage. It can stimulate the mesenchymal stem cells and fibroblasts and offer anti-inflammatory effects against the interleukin-1B through its growth factors content such as insulin-like growth factor 1 and transforming growth factor- β (28). Interestingly, PRP is considered as a biological therapy for tissue injury as it promotes the proliferation of synovium and cartilage derived cells (29). It also has a lubricant effect in the injected joint with significant decrease of the frictional force and wear resulting in a significant improvement of the clinical outcomes in symptomatic KOA (30,31).

Cole et al (32) compared intraarticular injection of PRP versus hyaluronic acid in patients with chronic KOA. They mentioned that PRP carried a better response regarding pain and disability, and they assume that such effects can be due to the anti-inflammatory properties of the PRP. Our results agree with findings of Khoshbin et al (33) who found that multiple intraarticular PRP injections can offer a good therapeutic effect in adult patients with mild to moderate OA with approximately 6 months duration.

In contrast to this work, Dallari et al (34) compared intraarticular injection (hip joint) of PRP versus hyaluronic acid in 111 patients with chronic hip joint OA. The study signified that PRP had offered better long-standing pain relief over 12 months in comparison to our study where we found that the pain relief was maintained up to 6 months only. We assume that such contrast could be due to the differences in joints involved and inclusion criteria. Bennell et al (35) investigated the effectiveness of PRP injection in the treatment of hip and knee OA through studying 15 randomized clinical trials. They stated that PRP is a promising safe treatment with short term (up to 12 months) relief for knee and hip OA.

Regarding to the frequency of PRP injection, Patel et al (36) compared the outcome following single and double PRP injections compared to a control group for early KOA at 6 weeks and 3 and 6 months. They concluded that there was a significant improvement in Western Ontario and McMaster Universities Osteoarthritis (WOMAC) scores during the whole study period when PRP was administered with no significant difference between single and double injections.

The demonstration of a greater sustained duration of benefits with PRF in comparison to the PRP in this study can be postulated through various mechanisms as follows: Sluijter et al (37) mentioned that PRF could offer a therapeutic role through immune modulation and decrease the stimulation of C-fibers as well as synaptic transmission. Similarly, Moffett et al (38) postulated that PRF could alleviate pain through the enhanced secretion of endogenous opioid precursor mRNA in some human cells. We think that the sustained and prolonged analgesic effect noted in the PRF group in this study can be assumed also to the disrupted nerve tissue because of protein denaturation and coagulation necrosis (39).

We have used Lequesne index of severity (13) which measures 3 important domains in OA; pain or discomfort and maximum distance walked and activities of daily living. The improvement was evident in both groups; however, it was better in the PRF group than the PRP group. A recent meta-analysis done by Han et al (40) compared the effectiveness of PRP versus hyaluronic acid. The pooled analysis of 3 studies demonstrated insignificant deference as regard to Lequesne index of severity. Another study done by Eyigor et al (41) investigated the value of intraarticular PRF of the

chronic KOA. They mentioned that the improvement was noted up to the fourth week only in Lequesne index of severity.

Limitations

The analgesics and physical therapy programs used may have some impact upon the results, but these were not recorded in the study. Additionally, there was no control group in the study to compare each group with.

CONCLUSION

Pulsed RF can offer more sustained pain relief and hence better patient satisfaction when compared to intraarticular injection of PRP in patients with chronic KOA. Both interventions offered comparable improvement in ISK and safe reliable outcomes.

Conflict of interest

The authors declare that they have no conflict of interest.

Funding

No external funding, the study was done and covered by institutional resources.

REFERENCES

- Litwic A, Edwards MH, Dennison EM, Cooper C. Epidemiology and burden of osteoarthritis. *Br Med Bull* 2013; 105:185-199.
- Helmick CG, Felson DT, Lawrence RC, et al; National Arthritis Data Workgroup. Estimates of the prevalence of arthritis and other rheumatic conditions in the United States. Part I. *Arthritis Rheum* 2008; 58:15-25.
- Nguyen US, Zhang Y, Zhu Y, Niu J, Zhang B, Felson DT. Increasing prevalence of knee pain and symptomatic knee osteoarthritis: Survey and cohort data. *Ann Intern Med* 2011; 155:725-732.
- Losina E, Weinstein AM, Reichmann WM, et al. Lifetime risk and age at diagnosis of symptomatic knee osteoarthritis in the US. *Arthritis Care Res (Hoboken)* 2013; 65:703-711.
- Felson DT, Naimark A, Anderson J, Kazis L, Castelli W, Meenan RF. The prevalence of knee osteoarthritis in the elderly. The Framingham Osteoarthritis Study. *Arthritis Rheum* 1987; 30:914-918.
- Srikanth VK, Fryer JL, Zhai G, Winzenberg TM, Hosmer D, Jones G. A meta-analysis of sex differences prevalence, incidence and severity of osteoarthritis. *Osteoarthritis Cartilage* 2005; 13:769-781.
- Al-Shammari SA, Khoja TA, al-Maatouq MA, al-Nuaim LA. High prevalence of clinical obesity among Saudi females: A prospective, cross-sectional study in the Riyadh region. *J Trop Med Hyg* 1994; 97:183-188.
- Karlsson J, Sjögren LS, Lohmander LS. Comparison of two hyaluronan drugs and placebo in patients with knee osteoarthritis: A controlled, randomized, double-blind, parallel-design multicentre study. *Rheumatology* 2002; 41:1240-1248.
- Bellamy N, Campbell J, Welch V, Gee TL, Bourne R, Wells GA. Intraarticular corticosteroid for treatment of osteoarthritis of the knee. *Cochrane Database Syst Rev* 2006; 2:CD005328.
- Korkmaz M, Erdoğan Y, Okur A, Göçmen AY, Günaydin İ. Comparison of the effects of intraarticular hyaluronic acid and anti-inflammatory drug treatments on the surgical intervention rates in patients with gonarthrosis. *Turk J Med Sci* 2013; 43:222-226.
- Kesikburun S, Yaşar E, Uran A, Adigüzel E, Yılmaz B. Ultrasound-guided genicular nerve pulsed radiofrequency treatment for painful knee osteoarthritis: A preliminary report. *Pain Physician* 2016; 19:E751-E759.
- Shen L, Yuan T, Chen S, Xie X, Zhang C. The temporal effect of platelet-rich plasma on pain and physical function in the treatment of knee osteoarthritis: Systematic review and meta-analysis of randomized controlled trials. *J Orthop Surg Res* 2017; 12:16. doi: 10.1186/s13018-017-0521-3
- Lequesne M, Mery C, et al. Indexes of severity for osteoarthritis of the hip and knee. *Scand J Rheumatology* 1987; 65:85-89. {Need third author.}
- World Medical Association Declaration of Helsinki: Ethical principles for medical research involving human subjects.

- JAMA 2013; 310:2191-2194.
15. Petersson IF, Boegård T, Saxne T, et al. Radiographic osteoarthritis of the knee classified by the Ahlbäck and Kellgren & Lawrence systems for the tibiofemoral joint in people aged 35 – 54 years with chronic knee pain. *Ann Rheum Dis* 1997; 56:493-496. doi:10.1136/ard.56.8.493
 16. Yasar E, Kesikburun S, Kılıç C, Yazar F, Tan AK. Accuracy of ultrasound-guided genicular nerve block: A cadaveric study. *Pain Physician* 2015; 18:E899-E904.
 17. Kesikburun S, Yaşar E, Uran A, et al. Ultrasound-guided genicular nerve pulsed radiofrequency treatment for painful knee osteoarthritis: A preliminary report. *Pain Physician* 2016; 19:751-759.
 18. American Association of Blood Banks technical manual committee. Method 6.11: Preparation of platelets from whole blood. In: Vengelen-Tyler V (ed). AABB Technical Manual, 13th ed. Bethesda, MD 1999, P 725. **{Need publisher.}**
 19. Likert R. A technique for the measurement of attitudes. *Archives of Psychology*. 1932. **{Need publisher and city.}**
 20. Mata J, Valentí P, Hernández B, et al. Study protocol for a randomized controlled trial of ultrasound-guided pulsed radiofrequency of the genicular nerves in the treatment of patients with osteoarthritis knee pain. *BMJ Open* 2017; 7:e016377.
 21. Choi WJ, Hwang SJ, Song JG, et al. Radiofrequency treatment relieves chronic knee osteoarthritis pain: A double-blind randomized controlled trial. *Pain* 2011; 152:481-487.
 22. Ahmed A, Arora D. Ultrasound-guided radiofrequency ablation of genicular nerves of knee for relief of intractable pain from knee osteoarthritis: A case series. *Br J Pain* 2018; 12:145-154.
 23. Tao H, Haiyuan W, Guangxiao L, Peng Y, Yuanyuan D. Systematic review and meta-analysis of 12 randomized controlled trials evaluating the efficacy of invasive radiofrequency treatment for knee pain and function. *BioMed Research International Volume* 2019. **{Need issue and pages.}{Can someone check the first and last names of the authors? I'm not sure I have it correct and in the text it is listed as Hong et al rather than Tao et al.}**
 24. Cheng PH, Kim HJ, Ottestad E, Narouze S. Ultrasound-guided injections of the knee and hip joints. *Tech Reg Anaesth Pain Manag* 2009; 13:191-197.
 25. Huntoon MA. Ultrasound in pain medicine: Advanced weaponry or just a fad? *Reg Anesth Pain Med* 2009; 34:387-388.
 26. Abd-Elseyed A, Anis A, Kaye AD. Radiofrequency ablation and pulsed radiofrequency for treating peripheral neuralgias. *Curr Pain Headache Rep* 2018; 22:5.
 27. Franco CD, Buvanendran A, Petersohn JD, et al. Innervation of the anterior capsule of the human knee: Implications for radiofrequency ablation. *Reg Anesth Pain Med* 2015; 40:363-368.
 28. van Buul GM, Koevoet WL, Kops N, et al. Platelet-rich plasma releasate inhibits inflammatory processes in osteoarthritic chondrocytes. *Am J Sports Med* 2011; 39:2362-2370.
 29. Osterman C, McCarthy MB, Cote MP, et al. Platelet-rich plasma increases anti-inflammatory markers in a human coculture model for osteoarthritis. *Am J Sports Med* 2015; 43:1474-1484.
 30. Sakata R, Reddi AH. Platelet-rich plasma modulates actions on articular cartilage lubrication and regeneration. *Tissue Engineering Part B: Reviews* 2016; 22:408-419.
 31. Sundman EA, Cole BJ, Karas V, et al. The anti-inflammatory and matrix restorative mechanisms of platelet-rich plasma in osteoarthritis. *Am J Sports Med* 2014; 42:35-41.
 32. Cole BJ, Karas V, Hussey K, Pilz K, Fortier LA. Hyaluronic acid versus platelet-rich plasma: A prospective, double-blind randomized controlled trial comparing clinical outcomes and effects on intra-articular biology for the treatment of knee osteoarthritis. *Am J Sports Med* 2017; 45:339-346.
 33. Khoshbin A, Leroux T, Wasserstein D, et al. The efficacy of platelet-rich plasma in the treatment of symptomatic knee osteoarthritis: A systematic review with quantitative synthesis. *Arthroscopy* 2013; 29:2037-2048.
 34. Dallari D, Stagni C, Rani N, et al. Ultrasound-guided injection of platelet-rich plasma and hyaluronic acid, separately and in combination, for hip osteoarthritis: A randomized controlled study. *Am J Sports Med* 2016; 44:664-671.
 35. Bennell KL, Hunter DJ, Paterson KL. Platelet-rich plasma for the management of hip and knee osteoarthritis. *Curr Rheumatol Rep* 2017; 19:24.
 36. Patel S, Dhillion MS, Aggarwal S, Marwaha N, Jain A. Treatment with platelet-rich plasma is more effective than placebo for knee osteoarthritis: A prospective, double-blind, randomized trial. *Am J Sports Med* 2013; 41:356-364.
 37. Sluijter ME, Teixeira A, Serra V, Balogh S, Schianchi P. Intra-articular application of pulsed radiofrequency for arthrogenic pain-report of six cases. *Pain Practice* 2008; 8:57-61.
 38. Moffett J, Fray LM, Kubat NJ. Activation of endogenous opioid gene expression in human keratinocytes and fibroblasts by pulsed radiofrequency energy fields. *Journal of Pain Research* 2012; 5:347.
 39. Shen WS, Xu XQ, Zhai NN, Zhou ZS, Shao J, Yu YH. Radiofrequency thermo-coagulation in relieving refractory pain of knee osteoarthritis. *American Journal of Therapeutics* 2017; 24:e693-700.
 40. Han Y, Huang H, Pan J, et al. Meta-analysis comparing platelet-rich plasma vs hyaluronic acid injection in patients with knee osteoarthritis. *Pain Med* 2019; 20:1418-1429.
 41. Eyigor C, Eyigor S, Akdeniz S, Uyar M. Effects of intra-articular application of pulsed radiofrequency on pain, functioning and quality of life in patients with advanced knee osteoarthritis. *J Back Musculoskelet Rehabil* 2015; 28:129-134.