



## Serine Protease Inhibitor Kazal type 1 (SPINK1) expression in Colorectal cancer: Immunohistochemical study

Shimaa H. Shabani, Tarek M. Elsaba<sup>1</sup>, Shereen M. Abd El Aziz<sup>2</sup>, Etemad Helmy<sup>3</sup>

Department of Oncologic Pathology, South Egypt Cancer Institute, Assiut University, Assiut, Egypt <sup>2</sup> Department of Oncologic Pathology, South Egypt Cancer Institute, Assiut University, Assiut, Egypt

<sup>3</sup> Department of Microbiology and Immunology, Faculty of Medicine, Assiut University, Assiut, Egypt <sup>4</sup> Department of Pathology, Faculty of Medicine, Assiut University, Assiut, Egypt

**Running title: SPINK1 immunohistochemistry and colorectal cancer Address correspondence to:**

Shimaa H. Shaban

Department of Oncologic Pathology, South Egypt Cancer Institute,  
Assiut University, Assiut, Egypt  
Tel: 00201090651710

E-mail: shimaashaban19@yahoo.com

Published at 1/10/2017

### Abbreviations:

.SPINK1: Serine Protease Inhibitor Kazal type1, CRC: Colorectal Cancer, TATI: Tumor Associated Trypsin Inhibitor, EGF: Epidermal Growth Factor, FFPET: Formalin Fixed Paraffin Embedded Tissue, SECI: South Egypt Cancer Institute, IRB: International Registry of Board

### Abstract

**Background:** Serine protease inhibitor kazal type 1 (SPINK1) was highly expressed in many cancer types and in colon, SPINK1 was involved in inflammation-induced colon cancer, proliferation and carcinogenesis. In this study, SPINK1 protein expression in colorectal cancer specimens was evaluated and correlated its expression with clinicopathological variables.

**Material and methods:** Formalin-fixed paraffin embedded tissue sections from 87 colorectal cancer specimens were stained with SPINK1 antibody using immunohistochemistry technique. Expression of SPINK1 was then analysed to evaluate its association with clinicopathological variables.

**Results:** High SPINK1 protein expression was detected in 75 (86.2%) of CRC specimens and was significantly associated with lymph-vascular invasion ( $p < 0.001$ ), and lymph node metastasis ( $p = 0.005$ ), and advanced clinical stage ( $p = 0.003$ ).

**Conclusion:** High SPINK1 protein expression is associated with lymph-vascular invasion and lymph node metastasis in colorectal cancer suggesting its role in invasion and metastases.

**Keywords:** Serine Protease Inhibitor Kazal type 1 SPINK1, Tumor Associated Trypsin Inhibitor TATI, colorectal Cancer CRC

## **Background**

Colorectal cancer (CRC) is a common malignant neoplasm, it is considered the third cancer worldwide after lung and breast cancers<sup>(1)</sup>. In 2012, 1.4 million cases of CRC were diagnosed, and 694,000 deaths due to CRC were observed<sup>(1)</sup>. The relative frequency of CRC in Egypt is about 9-12%<sup>(2)</sup>. In the most recent decade, the survival of patients with metastatic CRC has enhanced significantly due to the appearance of new medications and target treatments e.g: bevacizumab, cetuximab and panitumab<sup>(3)</sup>.

bevacizumab, cetuximab and panitumab<sup>(3)</sup>. The serine protease inhibitor Kazal type1 (SPINK1) is a synonym of the tumour-associated trypsin inhibitor (TATI) that was first detected in urine of ovarian cancer patients

<sup>(4)</sup>. Huhtala and his colleagues showed that TATI found in urine of ovarian cancer patients was identical to the human pancreatic trypsin inhibitor<sup>(5)</sup>. The serine protease inhibitor Kazal type1 (SPINK1) was at first segregated from bovine pancreas by Kazal and his colleagues in 1948 and was therefore called Kazal inhibitor<sup>(6)</sup>.

SPINK1 inhibits trypsin that prevents premature activation of trypsinogen in pancreatic acini and thus reduces tissue damage<sup>(7)</sup>. A

structural similarity has been found between SPINK1 and epidermal growth factor (EGF), and on the basis of these findings it has been proposed that SPINK1 act as a growth factor<sup>(8)</sup>. Normally, SPINK1 is expressed by liver, pancreas, colon and other gastrointestinal organs<sup>(9)</sup>.

In cancer, increased expression of SPINK1 was detected in cancers of ovary, prostate, breast

All patients diagnosed as primary colorectal adenocarcinoma within the period (2011-2013) and treated primary by surgery without prior neoadjuvant therapy with available FFPE blocks and clinicopathological data were included in this study. Recurrent colorectal adenocarcinoma, patients received neoadjuvant therapy prior to their surgery, and cases with unavailable tissue blocks or bladder, and GI tumors<sup>(10-14)</sup>. SPINK1 expression clinical data were excluded. All

available has been associated with decreased survival in many types of cancers. Elevated serum SPINK1 was a strong prognostic marker superior to CA125 in ovarian cancer<sup>(15)</sup>. Moreover, serum expression of SPINK1 in renal cell carcinoma was an independent prognostic factor<sup>(16)</sup>. In colorectal cancer, increased SPINK1 expression in tumour tissue was associated with bad prognosis<sup>(10)</sup>. However, Koskensalo, Louhimo, Hagstrom, Lundin, Stenman and Haglund (17) found that high expression of SPINK1 was associated with better prognosis. Hence the prognostic significance of tissue expression of SPINK1 in colorectal cancer remains controversial.

This study aims to assess the expression of SPINK1

protein in colorectal adenocarcinoma tissue and analyse the association between SPINK1 expression and different clinicopathological parameters.

## **Material and methods:**

### **Study cohort:**

This retrospective study included 87 formalin fixed paraffin embedded (FFPE) tissue specimens of colorectal adenocarcinoma that were retrieved from the archives of Pathology Department, South Egypt Cancer Institute (SECI) within the period from January 2011 to December 2013 after the approval of International Registry of Board (IRB) .

clinicopathological data of the patients included in the study were collected from the database system and patients' paper sheets.

### **Immunohistochemistry:**

Formalin-fixed, paraffin-embedded tissue sections were cut into 3-micron thickness and mounted on positively charged coated glass slides. Sections were deparaffinized and rehydrated through graded alcohols to distilled water. For antigen retrieval slides were incubated in (Tris EDTA) in a heated water bath at 90 for 45 minutes. Primary rabbit polyclonal anti- Human SPINK1, antibody (Catalog #213542, US Biological Life sciences, USA) at 1/200 concentration (optimum dilution) was applied for tissue sections and incubated for 30 minutes at room temperature in a humid chamber. After washing, immunostaining was performed using a universal staining kit "UltraVision Detection System Anti-Polyvalent, HRP/DAB (Ready-To-Use)" (LAB VISION corporation, catalogue # TP-015-HD, Fremont, California 94539-6406, USA) following the manufacturer's instructions. Finally, (DAB solution) was applied to the slides for 5- 10 minutes.

Mayer's haematoxylin, was used as a counter stain. Sections from normal pancreatic tissue were used as positive control. As a negative control, we used sections of tissue specific positive control and stained using the same protocol but with omitting the primary antibody.

### **SPINK1 assessment:**

SPINK1 protein was expressed in the cytoplasm. The immunostained slides were examined by two pathologists blinded to the clinicopathological data and SPINK1 was scored according to previous literatures<sup>(19)</sup> as follow: 0 (0%), 1(1-10%), 2 (11-50%), and 3 (>50%). SPINK1 expression was considered high when positivity was >50%, and low when positivity <50%<sup>(1)</sup>.

### **Statistical analysis:**

All statistics were performed using statistical package for Social Sciences (SPSS version 21). The association between SPINK1 protein

expression and clinicopathological variables was evaluated using chi-square test (as categorical data). Statistical significance defines as  $p < 0.05$ .

## **Results**

### **Pattern of SPINK1 expression:**

Immunostaining results showed that SPINK1 expression was high (positive in more than 50% of cells) in 75 (86.2%) of specimens, while 12 (13.8%) of specimens showed low SPINK1 expression (positive in less than 50% of cells). (Figure 1&2).

### **Association between SPINK1 protein expression and clinicopathologic variables:**

**Table 1 showed the distribution of SPINK1 expression in relation to patients' and tumor characteristics. High SPINK1 expression was**

significantly associated with lymph-vascular invasion ( $p < 0.001$ ), lymph node metastasis ( $p = 0.005$ ), and advanced clinical stage ( $p = 0.003$ ). Although, high SPINK1 protein expression was detected in 24/30 (80%), 42/48 (78%), and 9/9 (100%) of cases of grade I, grade II, and grade III respectively, but it was not reach statistical significance. Also, SPINK1 expression was not statistically significantly associated with age, gender, tumor size, tumor site, histologic type, perineural invasion, pathological tumour stage and distant metastasis.

## **Discussion**

SPINK1 is a serine protease inhibitor secreted by pancreatic cells that prevent premature activation of trypsinogen within pancreatic cells and prevent their autodigestion<sup>(7)</sup>. In many cancer types, high SPINK1 expression was associated with poor prognosis<sup>(9)</sup>. Studies done on CRC showed an association between SPINK1 expression and tumour size and metastasis<sup>(10)</sup>, and experiments conducted using colon cancer cell lines revealed that overexpression of SPINK1 induced invasion, angiogenesis and metastases<sup>(20)</sup>.

This study cohort revealed that SPINK1 overexpression was associated with lymph-vascular invasion and distant metastasis. These findings go in agreement with a study done by Gaber and his colleagues which revealed that high SPINK1 expression was associated with distant metastases to liver<sup>(10)</sup>. Moreover, using a mouse model, overexpression of SPINK1 in HT29 colon cancer cell lines induces lung metastasis<sup>(20)</sup>. Association of SPINK1 with distant metastasis not only observed in colorectal cancer but also in many cancer types. In a recent study, increased serum concentration of SPINK1 was detected in patients with metastatic breast cancer<sup>(12)</sup>. In addition, functional studies revealed that SPINK1

stimulates invasion in a prostate cancer cell line<sup>(21)</sup>. Furthermore, in bladder cancer, Marchbank et. al. 2013 found that SPINK1 stimulates the migration and invasion in bladder cancer cell lines<sup>(22)</sup>. The data of previous studies as well as ours suggest that SPINK1 may be involved in metastatic process.

Additional evidences showed that SPINK1 may enhance cancer invasion and metastases and giving explanations of its mechanism of action<sup>(10, 19)</sup>. One plausible explanation was given by an earlier study done by Scheving and his colleagues 1983, who found a structural similarity between SPINK1 and epidermal growth factor (EGF), and based on this finding SPINK1 was supposed to act as a growth factor. Later on, recent studies revealed that SPINK1 exert its action through epidermal growth factor receptors (EGFR). Using human pancreatic cancer cell lines Ozaki et. al. 2009 found that SPINK1 binds to EGFR inducing its phosphorylation and subsequent activation of mitogen-activated protein kinase (MAPK) pathway<sup>(23)</sup>. Moreover, induction of recombinant SPINK1 in benign immortalized prostate cell line induces invasiveness while SPINK1 was not able to restore invasiveness in EGFR-knockdown prostate cancer cell line<sup>(18)</sup>. These data supported that the oncogenic effect of SPINK1 was exerted through EGFR. Another plausible explanation is that SPINK1 down regulation in WiDr colon

## **References**

1. Chen YT, Tsao SC, Tsai HP, Wang JY, Chai CY. Serine protease inhibitor Kazal type 1 (SPINK1) as a prognostic marker in stage IV colon cancer patients receiving cetuximab based targeted therapy. *J Clin Pathol.* 2016;70(2):1-5.

adenocarcinoma cell line induces upregulation of metallothioneine (consider as a tumour suppressor gene)<sup>(24)</sup>. All these data support the role of SPINK1 in invasion and metastases.

In our study we observed a statistical significant association between high SPINK1 protein expression and advanced clinical stage. This data was in agreement with Chen et al; 2015 who found a positive correlation between high SPINK1 expression and advanced disease stage. These data suggest the association of SPINK1 and advanced tumour behavior. This could be explained by the evident structural similarity between PINK1 and EGF<sup>(8)</sup>.

Our study has a limitation that it is a retrospective study with a small sample size and is lacking follow up data which is needed to identify the prognostic significance of SPINK1.

**In conclusion** we found that high expression of SPINK1 was associated with lymph-vascular invasion, lymph node metastasis and advanced clinical stage, suggesting a role of SPINK1 in colorectal cancer invasion and metastasis and strengthen the rationale of using anti-SPINK1 as a targeted therapy. Further studies with larger

sample size , follow up data and chemotherapy regimens to identify prognostic and predictive value of SPINK1 are recommended.

2. Mahfouz EM, Sadek RR, Abdel-Latif WM, Mosallem FA, Hassan EE. The role of dietary and lifestyle factors in the development of colorectal cancer: case control study in Minia, Egypt. *Cent Eur J Public Health*. 2014;22(4):215-22.
3. De Divitiis C, Nasti G, Montano M, Fisichella R, Iaffaioli RV, Berretta M. Prognostic and predictive response factors in colorectal cancer patients: Between hope and reality. *World Journal of Gastroenterology : WJG*. 2014;20(41):15049-59.
4. Stenman U-H, Huhtala M-L, Koistinen R, Seppälä M. Immunochemical demonstration of an ovarian cancer-associated urinary peptide. *International Journal of Cancer*. 1982;30(1):53-7.
5. Huhtala ML, Pesonen K, Kalkkinen N, Stenman UH. Purification and characterization of a tumor-associated trypsin inhibitor from the urine of a patient with ovarian cancer. *The Journal of biological chemistry*. 1982;257(22):13713-6.
6. Kazal LA, Spicer DS, Brahinsky RA. Isolation of a crystalline trypsin inhibitor-anticoagulant protein from pancreas. *Journal of the American Chemical Society*. 1948;70(9):3034-40.
7. Sahin-Toth M. Human Mesotrypsin Defies Natural Trypsin Inhibitors: From Passive Resistance to Active Destruction. *Protein and Peptide Letters*. 2005;12(5):457-64.
8. Scheving LA. Primary amino acid sequence similarity between human epidermal growth factor-urogastrone, human pancreatic secretory trypsin inhibitor, and members of porcine secretin family. *Archives of biochemistry and biophysics*. 1983;226(2):411-3.
9. Rasanen K, Itkonen O, Koistinen H, Stenman UH. Emerging Roles of SPINK1 in Cancer. *Clin Chem*. 2016;62(3):449-57.
10. Gaber A, Johansson M, Stenman UH, Hotakainen K, Ponten F, Glimelius B, Bjartell A, Jirstrom K, Birgisson H. High expression of tumour-associated trypsin inhibitor correlates with liver metastasis and poor prognosis in colorectal cancer. *British journal of cancer*. 2009;100:1540-8.
11. Rink M, Park K, Volkmer BG, Xylinas E, Hansen J, Cha EK, Robinson BD, Hautmann R, Kufer R, Engel O, Chun FK, Dahlem R, Rubin MA, Shariat SF, Mosquera JM. Loss of SPINK1 expression is associated with unfavorable outcomes in urothelial carcinoma of the bladder after radical cystectomy. *Urologic oncology*. 2013;31(8):1716-24.
12. El-mezayen HA, Metwally FM, Darwish H. A novel discriminant score based on tumor-associated trypsin inhibitor for accurate diagnosis of metastasis in patients with breast cancer. *Tumour biology : the journal of the International Society for Oncodevelopmental Biology and Medicine*. 2014;35(3):2759-67.
13. Flavin R, Pettersson A, Hendrickson WK, Fiorentino M, Finn S, Kunz L, Judson GL, Lis R, Bailey D, Fiore C, Nuttall E, Martin NE, Stack E, Penney KL, Rider JR, Sinnott J, Sweeney C, Sesso HD, Fall K, Giovannucci E, Kantoff P, Stampfer M, Loda M, Mucci LA. SPINK1 protein expression and prostate cancer progression. *Clin Cancer Res*. 2014;20(18):4904-11.
14. Nissi R, Talvensaaari-Mattila A, Kuvaja P, Paakko P, Soini Y, Santala M. Claudin-5 is associated with elevated TATI and CA125 levels in mucinous ovarian borderline tumors. *Anticancer research*. 2015;35(2):973-6.
15. Venesmaa P, Stenman UH, Forss M, Leminen A, Lehtovirta P, Vartiainen J, Paavonen J. Pre-operative serum level of tumour-associated trypsin inhibitor and residual tumour size as prognostic indicators in Stage III epithelial ovarian cancer. *British journal of obstetrics and gynaecology*. 1998;105(5):508-11.
16. Lukkonen A, Lintula S, von Boguslawski K, Carpen O, Ljungberg B, Landberg G, Stenman UH. Tumor-associated trypsin inhibitor in normal and malignant renal tissue and in serum of renal-cell carcinoma patients. *Int J Cancer*. 1999;83(4):486-90.
17. Koskensalo S, Louhimo J, Hagstrom J, Lundin M, Stenman UH, Haglund C. Concomitant tumor expression of EGFR and TATI/SPINK1 associates with better prognosis in colorectal cancer. *PloS one*. 2013;8(10):e76906.
18. Ateeq B, Tomlins SA, Laxman B, Asangani IA, Cao Q, Cao X, Li Y, Wang X, Feng FY, Pienta KJ, Varambally S, Chinnaiyan AM. Therapeutic targeting of SPINK1-positive prostate cancer. *Science translational medicine*. 2011;3(72):72ra17.
19. Chen Y-T, Tsao S-C, Yuan S-SF, Tsai H-P, Chai C-Y. Serine Protease Inhibitor Kazal Type 1 (SPINK1) Promotes Proliferation of Colorectal Cancer Through the Epidermal Growth Factor as a

Prognostic Marker. *Pathology & Oncology Research*. 2015;21(4):1201-8.

20. Gouyer V, Fontaine D, Dumont P, de Wever O, Fontayne-Devaud H, Leteurtre E, Truant S, Delacour D, Drobecq H, Kerckaert JP, de Launoit Y, Bracke M, Gespach C, Desseyn JL, Huet G. Autocrine induction of invasion and metastasis by tumor-associated trypsin inhibitor in human colon cancer cells. *Oncogene*. 2008;27(29):4024-33.

21. Tomlins SA, Rhodes DR, Yu J, Varambally S, Mehra R, Perner S, Demichelis F, Helgeson BE, Laxman B, Morris DS, Cao Q, Cao X, Andr n O, Fall K, Johnson L, Wei JT, Shah RB, Al-Ahmadie H, Eastham JA, Eggener SE, Fine SW, Hotakainen K, Stenman U-H, Tsodikov A, Gerald WL, Lilja H, Reuter VE, Kantoff PW, Scardino PT, Rubin MA, Bjartell AS, Chinnaiyan AM. The Role of SPINK1 in ETS Rearrangement Negative Prostate Cancers. *Cancer cell*. 2008;13(6):519-28.

22. Marchbank T, Mahmood A, Playford RJ. Pancreatic secretory trypsin inhibitor causes autocrine-mediated migration and invasion in bladder cancer and phosphorylates the EGF receptor, Akt2 and Akt3, and ERK1 and ERK2. *American journal of physiology Renal physiology*. 2013;305(3):F382-9.

23. Ozaki N, Ohmuraya M, Hirota M, Ida S, Wang J, Takamori H, Higashiyama S, Baba H, Yamamura K. Serine protease inhibitor Kazal type 1 promotes proliferation of pancreatic cancer cells through the epidermal growth factor receptor. *Mol Cancer Res*. 2009;7(9):1572-81.

24. Tiwari R, Pandey SK, Goel S, Bhatia V, Shukla S, Jing X, Dhanasekaran SM, Ateeq B. SPINK1 promotes colorectal cancer progression by downregulating Metallothioneins expression. *Oncogenesis*. 2015;4:e162.

Table 1: Association between SPINK1/TATI and clinicopathologic characters

Variable	n	SPINK1 expression		P value
		Low<50%	High>50%	
All	87	12(13.8%)	75 (86.2%)	
Age ( years)				
<40	16 (18.4%)	2 (16.7%)	14 (18.7%)	0.868
≥40	71 (81.6%)	10(83.3%)	61 (81.3%)	
Gender				
Male	38 (43.7%)	5 (41.7%)	33 (44%)	0.880
Female	49 (56.3%)	7 (58.3%)	42 (56%)	
Tumor size				
<5 cm	59 (67.8%)	8 (66.7%)	51 (68%)	0.927
≥5 cm	28 (32.2%)	4 (33.3%)	24 (32%)	
Site				
Left side	70 (80.5%)	10(83.3%)	60 (80%)	0.787
Right side	17 (19.5%)	2 (16.7%)	15 (20%)	
Histologic type				
Adenocarcinoma	81 (93.1%)	12 (100%)	69 (92%)	0.597
Mucinous	5 (5.7%)	0 (0%)	5 (6.7%)	
Grade				
1	30 (34.5%)	6 (50%)	24 (32%)	0.289
2	48 (55.2%)	6 (50%)	42 (56%)	
Lymph-vascular invasion				
Negative	32(36.8%)	10(83.3%)	22 (29.3%)	<0.001*
Positive	55 (63.2%)	2 (16.7%)	53 (70.7%)	
Perineural invasion				
Negative	75 (86.2%)	11(91.7%)	64 (85.3%)	0.555
Positive	12 (13.8%)	1 (8.3%)	11 (14.7%)	

Tumor stage (T)				
1	3(3.4%)	0 (0%)	3(4%)	
2	11(12.6%)	4 (33.3%)	7(9.3%)	0.126
3	62(71.3%)	7 (58.3%)	55(73.3%)	
4	11(12.6%)	1 (8.3%)	10(13.3%)	
Lymphnode metastasis				
Negative				<b>0.005*</b>
Positive	47(54%)	11(91.7%)	36(48%)	
	40(46%)	1 (8.3%)	39(52%)	
Metastasis status (M)				
No	74 (85.1%)	11(91.7%)	63 (84%)	0.489
Yes	13 (14.9%)	1 (8.3%)	12 (16%)	
Stage				
Early stage	45 (51.7%)	11 (91.6%)	34 (45.3%)	<b>0.003*</b>
Advanced stage	42 (48.3%)	1 (8.3%)	41 (54.6%)	

**\*statistically significant ( $p < 0.05$ )**

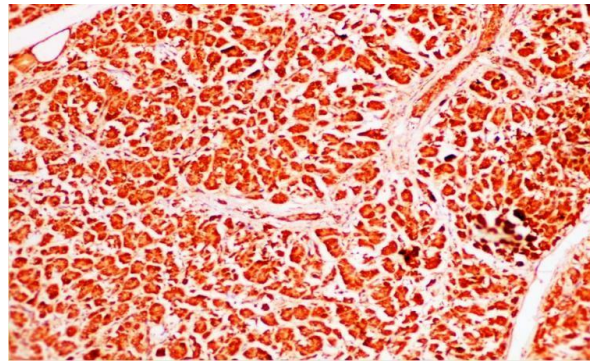
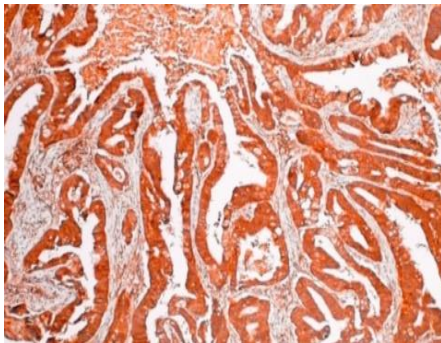
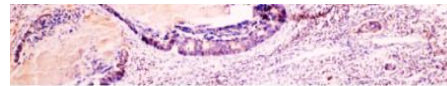


Figure 1: SPINK1 expression in pancreatic acini as a positive control (x10)



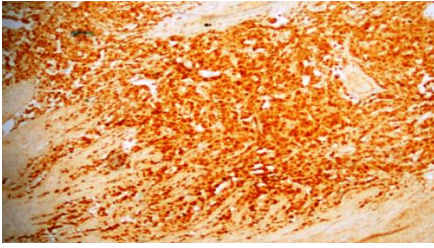
**A**



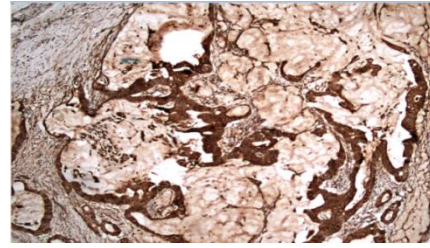
**B**

Figure 2: TATI/SPINK1 expression (x10)





**C**



**D**

1. High expression in more than 50% of cells in moderately differentiated adenocarcinoma stage 3.
2. Low/Negative expression in less than 50% of cells in well differentiated adenocarcinoma stage 1.
3. High expression in signet-ring carcinoma stage 3.
4. High expression in mucinous carcinoma stage 3.